

# Intracardiac thrombus in Behçet's disease

I. Ben Ghorbel, N. Belfeki, M.H. Houman

Department of Internal Medicine, University Hospital of La Rabta, Tunis, Tunisia

## SUMMARY

Behçet's disease (BD) is a multisystem inflammatory disorder. Intracardiac thrombus (ICT) formation is an uncommon but important complication of BD.

Of the cases of Behçet's disease, we selected those with ICT. All patients fulfilled the diagnostic criteria of the International Study Group of Behçet's disease. The ICT in each case was confirmed by ultrasonography, computed tomography and MRI. Clinical features and laboratory parameters were determined.

Among our 518 patients with BD, 8 were diagnosed as having intracardiac thrombus (ICT). All were male; the mean age at the time of the ICT diagnosis was 30.8 years. The main presenting symptoms were hemoptysis, chest pain, and dyspnea. It was associated with pulmonary artery aneurysm and vena cava thrombosis in 3 cases each, pulmonary embolism, and lower limbs deep venous thrombosis in 1 case each. The coexistence of other cardiac complications was as follows: pericarditis in 2 cases, myocarditis, endomyocardial fibrosis, and coronary arteritis with consequent myocardial infarction in one case each. In all cases, echocardiography was sufficient to reach the diagnosis. Chest computed tomography performed in all cases led to the diagnosis of associated pulmonary vasculo-Behçet lesions in 4 cases. All patients received colchicine, anticoagulation, and corticosteroids. Seven patients were on immunosuppressant agents (2 patients received azathioprine and 5 cyclophosphamide). Clinical remission with ICT resolution was observed in 5 cases. Combined immunosuppressive therapy with prednisone and cyclophosphamide might be needed to treat ICT due to BD.

**Key words:** Behçet's disease; Intracardiac thrombus.

Reumatismo, 2016; 68 (3): 148-153

## INTRODUCTION

Behçet's disease (BD) is a systemic inflammatory disease having a chronic and prolonged course with 4 major symptoms: oral and genital ulcerations, eye disease and cutaneous manifestations, as well as other multisystem involvement (1). The diagnosis is made on the basis of the criteria proposed by the International Study Group (ISG) for BD in 1990 (2). Intracardiac thrombus (ICT) is an uncommon and serious complication with difficult management because of the risk of thrombosis recurrence even after surgical resection of the thrombus (3). We report herein a case series of eight BD patients with ICT, and discuss the difficulties of managing such a rare aspect of BD.

## CASE REPORTS

### Case 1

A 38-year old male patient who had already been diagnosed with BD, recurrent deep

venous thrombosis of lower limbs, and pulmonary embolism (PE) arrived at our hospital with progressive shortness of breath, hemoptysis and chest pain. On physical examination, ulcer scars on the scrotum and oral mucosa and pseudofolliculitis were found. Electrocardiogram (ECG) showed bifascicular block, and chest X-ray a cardiomegaly.

Cardiac echography revealed dilated right ventricle seat of intraluminal thrombus, apical hypokinesis, and impaired left ventricular ejection fraction (LVEF) of 44%. Thoracic computed tomography (CT) excluded any associated pulmonary arteries involvement. A combination of 60 mg a day of prednisone, 1 mg a day of colchicine, and 4 mg a day of acenocoumarol, was administered. Four months later, echocardiography showed a complete resolution of the ICT and biventricular dilatation, and an impaired LVEF of 38%. Two years later, the patient was still being monitored, without recurrence.

Corresponding author  
Nabil Belfeki

Department of Internal Medicine  
University Hospital of La Rabta  
Rue Jebel Lakhdar, 1002, Tunis, Tunisia  
E-mail: belfeki.nabil@gmail.com

**Case 2**

A 39-year old male patient was admitted to our hospital with cough, dyspnea, and mild hemoptysis of unknown origin. He had had recurrent oral ulcers for one year. On physical examination, tachypnea, and healing scars from genital ulcers were found. The pathergy test was positive. Thoracic CT showed multiple pulmonary arterial aneurysms (PAA) partially thrombosed with multiple infarction and right intraventricular thrombus. Cardiac echography and cardiac magnetic resonance imaging (MRI) confirmed the presence of a 4-centimeter wide thrombus adherent to the side face of the right ventricle. The patient fulfilled the ISG criteria for the diagnosis of BD (2). High doses of prednisone and colchicine associated with monthly pulses of cyclophosphamide were administered. We ordered heparin therapy, followed by oral anticoagulation. Cyclophosphamide was switched to azathioprine. After 24 months, thoracic CT and echocardiography showed the persistence of a calcified right intra ventricular thrombus and regression of aneurysms. Otherwise, the patient was free of symptoms. The current follow-up is 5-years.

**Case 3**

A 25-year old male patient was admitted with persistent cough and hemoptysis. He had recurrent oral aphthosis and pseudofolliculitis on the trunk. Thoracic CT revealed right auricular mass and confirmed pulmonary embolism. The pathergy test was positive. An assessment of thrombophilia with a dosage of protein C, S, antithrombin, homocysteinemia, screening of factor V Leiden mutation, antinuclear antibodies and antiphospholipid antibodies was negative. Antineutrophil cytoplasm antibody test and tumor markers were negative. The patient underwent a thrombectomy and received oral anticoagulation. Three years later, he appeared with shortness of breath. Cardiac echography showed a recurrent right auricular thrombus despite an appropriate anticoagulation. According to the ISG criteria, the diagnosis of BD was retained. A combination of monthly intra-

venous cyclophosphamide pulses, prednisone, and colchicine was administered. Acenocoumarol was maintained. Three months later, an echocardiogram showed a complete resolution of ICT. Azathioprine replaced cyclophosphamide after one year. Six years later, the patient was still being followed, without recurrence.

**Case 4**

A 30-year old male patient with a past history of BD complicated by arterial thrombosis and ocular involvement, and well stabilized with immunosuppressants, steroids and long-term oral anticoagulation. He appeared with dyspnea, abdominal pain, and lower limb edema. On physical examination, abdominal ascites was detected. Thoraco-abdominal CT showed inferior vena cava thrombosis and hepatic veins thrombosis. Echocardiography revealed a serpentine mass on the right atrium and mild pericardial effusion. Doppler ultrasound of lower limbs confirmed a right superficial femoral vein thrombosis and left posterior tibial vein thrombosis. Protein C, S, antithrombin levels, the antiphospholipid antibodies, and the homocysteinemia were within normal range. Monthly pulses of cyclophosphamide, prednisone, colchicine, and acenocoumarol were administered. Six months later, echocardiography showed persistent intra auricular thrombus. The patient was still being symptomatic with mild hemoptysis, had developed a chronic heart failure, and the right intra auricular thrombus persisted. He refused thrombectomy and died 4-years later.

**Case 5**

A 29-year old male patient with past history of deep vein thrombosis on lower limbs had been treated 3-years before with oral anticoagulation for 12 months. He was admitted with headache, and chest pain at rest. On physical examination, dilated veins over the arms and anterior chest wall, edema of the face, and oral aphthosis were detected. The pathergy test was positive. ECG showed diffuse microvoltage. Thoracic CT showed superior and inferior vena cava thrombosis, left basal PE, right intra

auricular thrombus, and mild pericardial effusion. Echocardiography confirmed the presence of a floating thrombus in the right atrium. The patient fulfilled the ISG criteria for the diagnosis of Behçet's disease. Intravenous heparin treatment was started for the extensive venous thrombosis and replaced with acenocoumarol. A combination of azathioprine, prednisone, and colchicine was administered. Echocardiography and CT controls confirmed persistent intra auricular thrombus and showed superior vena cava thrombosis. The patient developed dysphonia. He refused surgery and died of massive hemoptysis 3-years later.

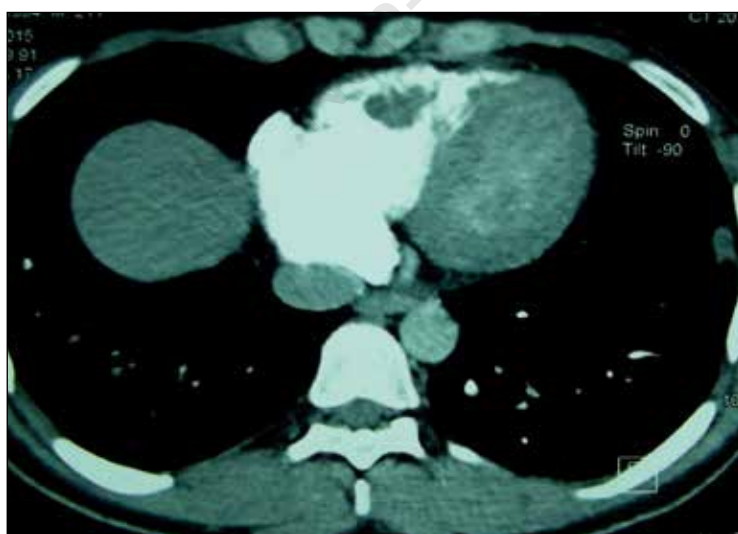
### Case 6

A 33-year old male patient with past history of recurrent bifocal ulcers, pseudofolliculitis and cerebral vein thrombosis was hospitalized with chest pain, prolonged fever, and abundant hemoptysis. Chest CT showed thrombosed aneurysm of the inferior lobar pulmonary artery, and right intraventricular thrombus (Figure 1). Echocardiography and cardiac MRI confirmed right intraventricular thrombus (Figure 2). BD was retained. The patient first received oral anticoagulation, steroids, and colchicine. He remained symptomatic with hemoptysis and the cardiac thrombus

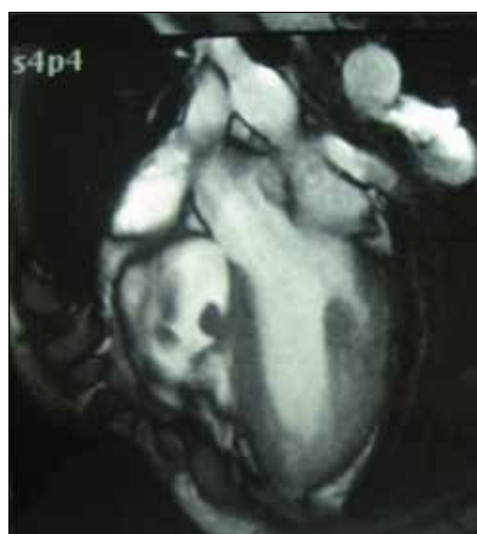persisted. Thrombectomy was eventually realized. Pathological findings concluded with fibrinocruoric thrombi and endomyocardial fibrosis. Four months later, cardiac echocardiography showed a thrombus recurrence. Monthly intravenous cyclophosphamide pulses were added to first treatment, later replaced with azathioprine. CT and echocardiography control at 12-months showed a complete resolution of intraventricular thrombi and a decrease in PAA. The patient is still asymptomatic. The current follow-up is 10-years.

### Case 7

A 28-year old male smoker of 20 cigarettes a day was admitted to our hospital with severe chest pain. ECG showed negative T waves in inferior leads. A non-ST elevation myocardial infarction was diagnosed and a thrombolytic therapy was immediately administered. This early strategy relieved the chest pain. Coronary arteriography showed an aneurysm three centimeters wide, sitting in the right coronary artery associated with an upstream stenosis. Echocardiography revealed right intraventricular thrombus confirmed on cardiac MRI (Figure 3). The patient received first an anti ischemic treatment ( $\beta$  blockers, inhibitor of angiotensin converting enzyme) with appropriate an-



**Figure 1** - Cardiac magnetic resonance image showing right intraventricular cardiac thrombus.

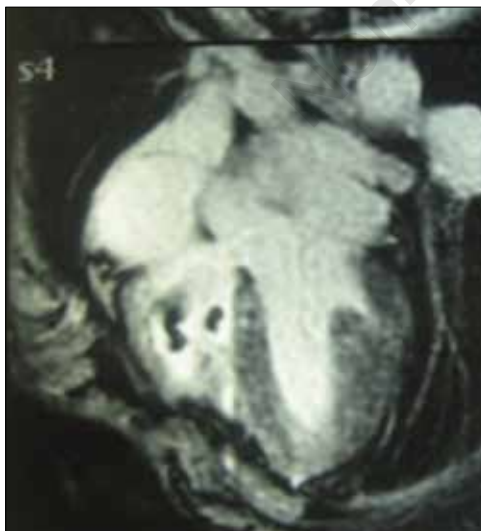

**Figure 2** - Cardiac magnetic resonance image (four chamber view) showing two right intracardiac thrombi.

ticoagulation. His past history revealed recurrent episodes of bifocal ulcers and an episode of anterior uveitis. He fulfilled the ISG criteria for the diagnosis of BD. Prednisone and monthly pulses of cyclophosphamide were administered. Control coronary arteriography realized at the sixth cycle of cyclophosphamide showed an improvement of the size of the aneurysm and control echocardiography revealed a complete resolution of right ventricular thrombus. Cyclophosphamide was replaced by azathioprine. The patient is now regularly seen in our outpatient clinic and follow-up is 8 years.

### Case 8

A 25-year old patient with BD was admitted to the hospital with complaints of progressive dyspnea and fatigue for a couple of months. Echocardiography revealed right intraventricular thrombosis and CT thorax concluded with PE. A thrombectomy and oral anticoagulation were administered. One year later, he appeared with aphasia. Cranial CT concluded there had been an ischemic stroke, and echocardiography revealed a recurrence of right intraventricular thrombus. Thoracic CT showed multiple thrombosed PAA, and inferior vena cava thrombosis. Cyclophosphamide pulses and



**Figure 3** - Echocardiography revealed right intraventricular thrombus confirmed on cardiac magnetic resonance imaging.

corticosteroids associated with oral anticoagulation were administered. Resolution was observed within 24 months. The follow-up is 6-years.

### DISCUSSION

Cardiac complications (up to 6% of BD patients) include pericarditis, endocarditis with valvular regurgitation, myocardial lesions (myocardial infarction, myocarditis, and endomyocardial fibrosis), and ICT (4). Table I summarizes the 8 reports. ICT is a rare and serious complication. It is reported mostly in case reports. After a cumulative literature search, we found 93 cases previously published in 77 reports in which BD was associated with ICT (4). Among 518 BD patients in our department, the prevalence of ICT was 1.54%. Clinical presentation of the ICT remains unspecific with dyspnea, hemoptysis, or fever. In our series, ICT was associated with PAA, vena cava thrombosis, lower limbs deep venous thrombosis in 3 cases each, PE in 1 case. In the literature, ICT is associated with PE in 60%, vena cava thrombosis in 40%, and PAA in 38.3% (5, 6). The coexistence of other cardiac complications was as follows: pericarditis in 2 cases, myocarditis, endomyocardial fibrosis, and coronary arteritis with consequent myocardial infarction in one case each. ICT is located usually in the right side of the heart, the right ventricle being the most common location (6). Involvement of the left heart has been rarely reported (7). In our case series, the right heart was involved in all cases with right ventricular thrombosis in 5 cases and right atrial thrombosis in 3 cases. The echocardiography is generally sufficient to reveal this complication. The main differential diagnoses are primary heart tumour and infectious endocarditis (8). With our patients, we can reasonably and retrospectively exclude myxoma and endocarditis in view of clinical context, epidemiologic data, and the effect immunosuppressive and anticoagulation therapy. Imaging tests such as CT chest and MRI could be helpful in the assessment of associated thoracic manifestations of BD including thrombus

**Table 1** - Clinical features, management, and outcome in Behçet's disease patients with intracardiac thrombus.

Case	Gender/ Age (y)	Clinical features	ICT site	ICT Diagnostic tool(s)	Associated cardiovascular involment	Treatment	Outcome
1	Male/38	Dyspnea Chest pain Hemoptysis	Right ventricle	Echocardiography	Myocarditis	Prednisone Colchicine OAC	ICT resolution Chronic cardiac failure Clinical remission
2	Male/39	Cough Dyspnea Hemoptysis	Right ventricle	Echocardiography Cardiac MRI	PAA PE	Prednisone CYP Colchicine OAC Azathioprine	PAA resolution ICT persistence
3	Male/25	Cough Hemoptysis	Right atrium	Thoracic CT	PE	Prednisone CYP Colchicine OAC Azathioprine	ICT resolution Clinical remission
4	Male/30	Dyspnea Right heart failure	Right atrium	Echocardiography	Pericarditis Inferior vena cava thrombosis Hepatic, Femoral, Tibial vein thrombosis	Prednisone CYP Colchicine OAC Azathioprine	Liver cirrhosis Chronic heart failure ICT persistence Death
5	Male/29	Chest pain headache	Right atrium	Echocardiography Chest CT	Pericarditis Superior and inferior vena cava thrombosis	Prednisone Azathioprine Colchicine OAC	ICT persistence Massive hemoptysis Death
6	Male/33	Chest pain Hemoptysis Fever	Right ventricle	Echocardiography Chest CT Cardiac MRI	PAA Endomyocardial fibrosis	Thrombectomy Prednisone CYP Colchicine OAC Azathioprine	ICT resolution PAA improvement Clinical remission
7	Male/28	Chest pain	Right ventricle	Echocardiography Chest CT Cardiac MRI	Aneurysm and stenosis of right coronary artery Myocardial infarction	Prednisone CYP Colchicine OAC Azathioprine	ICT resolution Aneurysm size improvement
8	Male/25	Dyspnea Fatigue	Right ventricle	Echocardiography	PAA Inferior vena cava thrombosis	Thrombectomy OAC Prednisone CYP Azathioprine	ICT resolution Clinical remission

ICT, intracardiac thrombus; MRI, magnetic resonance imaging; PAA, pulmonary arterial aneurysms; PE, pulmonary embolism; CT, computed tomography.

of the systemic veins and pulmonary arteries (8). The pathogenic mechanism underlying thrombotic propensity in patients with BD is not completely understood. It is however reported that endothelial cell ischemia or disruption leads to enhancement of platelet aggregation (9). So far, none of the thrombophilic factors were shown to be associated with the thrombotic tendency observed in BD. A defect of fibrinolysis and hyperhomocysteinemia were however suggested (10, 11). The current data indicates that the pathogenesis of thrombosis in BD is not due to coagulation abnormalities (12). In previous reports, initiation of combination therapy for Behçet's disease with

prednisone and an immunosuppressant was associated with the resolution (13). In our case study, 7 patients underwent an immunosuppressant agent on attack treatment. They were divided into 2 groups: 2 patients received azathioprine, and 5 cyclophosphamide. Persistence of ICT was observed in all patients treated with azathioprine and in one case with cyclophosphamide. Azathioprine is not effective in preventing thrombotic complications according to the results observed in both azathioprine trials (14, 15). There are no real recommendations in the management of cardiac involvement due to BD. This case series confirmed the success of monthly pulses of cyclophos-



phamide and high dose corticosteroids, followed by azathioprine. Further studies are needed to confirm these conclusions. Anticoagulation in vasculo-Behçet remains debatable. There are no controlled studies, or evidence of benefit from uncontrolled experience with anticoagulants, antiplatelet or antifibrinolytic agents in vasculo-Behçet. In fact, thrombi in BD adhere to the vessel wall and do not result in emboli. Thus, the European League Against Rheumatism (EULAR) does not recommend the use of anticoagulants in the management of thrombosis (16). Our reports preceded these recommendations. Moreover, we observed recurrent thrombosis despite appropriate anticoagulation and confirm thereafter the success of immunosuppressive agents in one patient (case 3).

Desbois et al., in a retrospective cohort of 807 BD patients, concluded that immunosuppressive agents in BD patients reduced thrombosis relapse (17).

Furthermore, our experience with surgery is not supported by controlled studies because of the risk of recurrence and post-operative complications. It has to be limited to cases with massive thrombosis recurrence despite an optimal medical treatment, and when there is a cardiac congestion. Fibrinolytic therapy is seldom used and has also been unsuccessful (12).

## ■ CONCLUSIONS

ICT is a rare and serious complication in BD. Because pulmonary involvement (PAA and PE) and ICT were frequently and concomitantly encountered, we propose that pulmonary involvement might be investigated by thoracic CT in all BD patients with ICT. Based on our experience and other reports, treatment of ICT is mainly with immunosuppressives. Surgery carries a high risk of mortality.

**Funding:** this research received no grant from any funding agency in the public, commercial or not-for-profit sectors.

**Disclosures:** the Author(s) declare(s) that there is no conflict of interest.

## ■ REFERENCES

1. Davatchi F, Shahram F, Chams-Davatchi C, et al. Behçet's disease: from east to west. *Clin Rheumatol.* 2010; 29: 823-33.
2. [No authors listed]. International Study Group for Behçet's Disease Criteria for diagnosis of Behçet's disease. *Lancet* 1990; 335: 1078-80.
3. Geri G, Wechsler B, Thi Huong du L, et al. Spectrum of cardiac lesions in Behçet disease: a series of 52 patients and review of the literature. *Medicine (Baltimore).* 2012; 91: 25-34.
4. Aksu T, Tufekcioglu O. Intracardiac thrombus in Behçet's disease: four new cases and a comprehensive literature review. *Rheumatol Int.* 2015; 35: 1269-79.
5. Desbois AC, Wechsler B, Cluzel P, et al. Cardiovascular involvement in Behçet's disease. *Rev Med Interne.* 2014; 35: 103-11.
6. Mogulkoç N, Burgess IM, Bishop PW. Intracardiac thrombus in Behçet's disease. A systematic review. *Chest.* 2000; 118: 479-87.
7. Vanhaleweyk G, el-Ramahi KM, Hazmi M, et al. Right atrial, right ventricular and left ventricular thrombi in Behçet's disease. *Eur Heart J.* 1990; 11: 957-9.
8. Ben Ghorbel I, Ibn Elhadj Z, Khanfir M, et al. Intracardiac thrombus in Behçet's disease. A report of three cases. *J Mal Vasc.* 2004; 29: 159-61.
9. Schmitz-Huebner U, Knop J. Evidence for an endothelial cell dysfunction in association with Behçet's disease. *Thromb Res.* 1984; 34: 277-85.
10. Yurdakul S, Hekim N, Soysal T, et al. Fibrinolytic activity and-dimer levels in Behçet's syndrome. *Clin Exp Rheumatol.* 2005; 23: 53-8.
11. Siva A, Kantarci OH, Saip S, et al. Behçet's disease: diagnostic and prognostic aspects of neurological involvement. *J Neurology.* 2001; 248: 95-103.
12. Seyahi E, Yurdakul S. Behçet's syndrome and thrombosis. *Mediterr J Hematol Infect Dis.* 2011; 3: e2011026.
13. Hatemi G, Silman A, Bang D, et al. Management of Behçet disease: a systematic literature review for the European League Against Rheumatism evidence-based recommendations for the management of Behçet disease. *Ann Rheum Dis.* 2009; 68: 1528-34.
14. Yazici H, Pazarli H, Barnes CG, et al. A controlled trial of azathioprine in Behçet's syndrome. *N Engl J Med.* 1990; 322: 281-5.
15. Hamuryudan V, Ozyazgan Y, Hizli N, et al. Azathioprine in Behçet's syndrome: effects on long-term prognosis. *Arthritis Rheum.* 1997; 40: 769-74.
16. Hatemi G, Silman A, Bang D, et al. EULAR recommendations for the management of Behçet disease. *Ann Rheum Dis.* 2008; 67: 1656-62.
17. Desbois AC, Wechsler B, Resche-Rigon M, et al. Immunosuppressants reduce venous thrombosis relapse in Behçet's disease. *Arthritis Rheum.* 2012; 64: 2753-60.