

Reumatismo - The Italian Journal of Rheumatology

<https://www.reumatismo.org/reuma>

eISSN 2240-2683

Publisher's Disclaimer. E-publishing ahead of print is increasingly important for the rapid dissemination of science. The Early Access service lets users access peer-reviewed articles well before print/regular issue publication, significantly reducing the time it takes for critical findings to reach the research community.

These articles are searchable and citable by their DOI (Digital Object Identifier).

Reumatismo is, therefore, E-publishing PDF files of an early version of manuscripts that have undergone a regular peer review and have been accepted for publication, but have not been through the copyediting, typesetting, pagination, and proofreading processes, which may lead to differences between this version and the final one.

The final version of the manuscript will then appear in a regular issue of the journal.

The E-publishing of this PDF file has been approved by the authors.

Please cite this article as:

Rizzo C, Grazzini S, Conticini E, et al. Small molecules in idiopathic inflammatory myopathies: a systematic review and a multicenter case series about Janus kinase inhibitors and apremilast. *Reumatismo* doi: 10.4081/reumatismo.2025.1718

Submitted: 26-02-2024

Accepted: 06-08-2024

 © the Author(s), 2025
Licensee PAGEPress, Italy

Note: The publisher is not responsible for the content or functionality of any supporting information supplied by the authors. Any queries should be directed to the corresponding author for the article.

All claims expressed in this article are solely those of the authors and do not necessarily represent those of their affiliated organizations, or those of the publisher, the editors and the reviewers. Any product that may be evaluated in this article or claim that may be made by its manufacturer is not guaranteed or endorsed by the publisher.

Small molecules in idiopathic inflammatory myopathies: a systematic review and a multicenter case series about Janus kinase inhibitors and apremilast

Chiara Rizzo,¹ Silvia Grazzini,² Edoardo Conticini,² Hector Chinoy,^{3,4} Roberto D'Alessandro,² Federica Camarda,¹ Luca Cantarini,² Bruno Frediani,² Giuliana Guggino,¹ Lidia La Barbera¹

¹Rheumatology Unit, Department of Health Promotion, Mother and Child Care, Internal Medicine and Medical Specialties, University of Palermo, Italy; ²Rheumatology Unit, Department of Medicine, Surgery and Neurosciences, University of Siena, Italy; ³Department of Rheumatology, Salford Royal Hospital, Northern Care Alliance NHS Foundation Trust, Manchester Academic Health Science Centre, Salford, United Kingdom; ⁴Division of Musculoskeletal and Dermatological Sciences, Faculty of Biology, Medicine and Health, University of Manchester, United Kingdom

Correspondence: Silvia Grazzini, Rheumatology Unit, Department of Medicine, Surgery and Neurosciences, University of Siena, Viale Mario Bracci 14, 53100, Siena, Italy.

Tel.: 0039 3498452830.

E-mail: grazzini.reumatologia@gmail.com

Key words: idiopathic inflammatory myopathies, myositis, treatment, JAK inhibitors, apremilast, tsDMARDs.

Contributions: CR, SG, EC, LLB, FC, writing - original draft and figure preparation; SG, CR, LLB, EC, RD, FC, collecting data, literature research; CR, SG, LC, BF, GG, HC, LLB, editing, visualization, supervision, project administration.

Conflict of interest: the authors declare that they have no competing interests, and all authors confirm accuracy.

Ethics approval and consent to participate: not applicable.

Patient consent for publication: all patients gave informed written consent for the publication of identifying information/images in an online open-access publication.

Funding: this research did not receive any specific grant from funding agencies in the public, commercial, or not-for-profit sectors.

Availability of data and materials: data used in our evidence synthesis were extracted from published manuscripts identified in our systematic review. Data regarding patients are not available.

Summary

Objective. Idiopathic inflammatory myopathies (IIM) are rare autoimmune diseases that primarily affect striated muscles; skin, joints, and lungs may be involved with different degrees of severity. Traditional treatment relies on high-dose glucocorticoids and conventional synthetic disease-modifying antirheumatic drugs.

Methods. A growing amount of evidence is demonstrating the potential role of novel treatments in the management of IIM. We report our experience with Janus kinase inhibitors (JAKi) in these conditions and review the current evidence for the use of small molecules in real-life clinical practice.

Results. A total of 41 papers were retrieved from PubMed, 37 papers concerning IIM and JAKi, and 4 papers concerning IIM and apremilast.

Conclusions. An overall good efficacy was evidenced in IIM-associated skin lesions, including rash, ulcers, and calcinosis. If present, muscle and joint involvement demonstrated a good response to therapy, while it was not possible to draw any conclusion about dysphagia. No life-threatening adverse events were reported.

Introduction

Idiopathic inflammatory myopathies (IIM) are a heterogeneous group of rare, autoimmune diseases, primarily affecting striated muscles. Historically divided into dermatomyositis (DM), polymyositis (PM), inclusion body myositis (IBM) and antisynthetase syndrome (ASS), they have been recently classified by the American College of Rheumatology/European League Against Rheumatism criteria in ASS, DM, immune-mediated necrotizing myopathies (IMNM), IBM and overlap syndrome, including juvenile forms of IIM too (1). In the workup, the presence of myositis-specific or associated autoantibodies has further empowered both diagnosis and prognosis in IIM.

IIM may affect muscle, skin, joints, gastrointestinal (GI) tract and lungs with different degrees of severity. The pivotal symptom is progressive proximal muscle weakness, whereas lungs can be affected in form of interstitial lung disease (ILD), rapidly progressive (RP) in the most severe cases, and skin involvement usually manifests with pathognomonic lesions, such as Gottron's papules, shawl and V-sign, or heliotrope rash. GI tract can be involved, causing dysphagia.

Considering the rarity of these diseases and their variable clinical phenotype, treatment is usually challenging. Currently, there are no clear-cut guidelines or a standardized therapy approach for IIM: glucocorticoids (GC), together with traditional immunomodulators or immunosuppressive drugs, such as conventional synthetic disease-modifying antirheumatic drugs (csDMARDs), remain the cornerstone of treatment in IIM, coupled with alternative approaches that include intravenous immunoglobulins (IVIg) and biological disease modifying anti-rheumatic drugs (bDMARDs) (2-4). In the last decade, a growing body of evidence has been published accounting for the important role of bDMARDs, especially rituximab (RTX), in the management of IIM (5). In addition, an emerging number of reports have highlighted a certain degree of efficacy of targeted synthetic DMARDs (tsDMARDs), in particular Janus kinase inhibitors (JAKi), while evidence about apremilast (APR) is still very poor.

Therefore, the aim of our review is to report our experience with JAKi in IIM and review the current evidence for tsDMARDs in real-life clinical practice.

Methods

We described our experience employing JAKi in IIM patients. A literature review from the electronic database was conducted in accordance with the Preferred Reporting Items for Systematic Reviews and Meta-Analyses recommendations to generate research-based evidence. The PubMed database was searched on 23/08/2023, looking for keywords like *dermatomyositis*, *antisynthetase syndrome*, *inclusion bodies myositis*, *polymyositis*, *ASS*, *DM*, *IBM*, *PM*, each combined with *janus kinase inhibitors*, *apremilast*, variously combined with each other. Reviews, studies on juvenile DM and studies that were not applicable because they addressed other diseases were excluded. Duplicates were deleted. We did not include IMNM because of the different disease pathogenesis compared to other IIM. We did not apply any linguistic or temporal restriction. All articles were independently reviewed by two authors (Figure 1).

Results

Case reports

Herein we report three patients with anti-melanoma differentiation-associated gene 5 (*MDA5*) DM, one anti-Mi2 DM, and two overlap syndrome anti-Jo1 ASS/seropositive rheumatoid arthritis (RA), who have been successfully treated with tofacitinib (TOF) or baricitinib (BAR).

Patient 1. A 44-year-old man without relevant previous diseases came to our rheumatology clinic in March 2021 complaining about shoulders and legs weakness, fever, myalgias and progressive dyspnea.

Clinical examination highlighted different skin lesions, such as heliotrope rash, acral ulcers and V-sign. The power doppler ultrasonography muscle exam (PDUS) demonstrated advanced atrophy (grade 4, according to the Siena Myositis Ultrasound Grading Scale, SMUGS) of quadriceps and mild doppler signal (grade 1-2 of SMUGS), without edema (6). A high-resolution computed

tomography (HRCT) of the lungs revealed the presence of parenchymal consolidations with peripheral areas of ground glass (GG). Lung disease was complicated by pneumomediastinum and pneumothorax. The patient was thus hospitalized with a diagnosis of DM with RP-ILD. Laboratory tests detected the positivity of anti-MDA5 and high levels of C-reactive protein (CRP) (3.64 mg/dL) and ferritin (1328 ng/mL).

During hospitalization, in addition to oral prednisone (PDN) 1 mg/kg/day and oxygen supply, he was treated with 5-days methylprednisolone (MPDN) 1000 mg pulse therapy, plasma exchange (PEX), intravenous IVIg – and IV cyclophosphamide (CYC).

Despite this approach, pulmonary function declined rapidly, and TOF 5 mg twice a day was introduced as rescue therapy. After one month, the patient was discharged in stable clinical conditions.

At the 2-month follow-up, the pulmonary inflammation was still active as documented by HRCT and a new cycle of CYC + 3-days MPDN 1000 mg was performed.

In July 2021, the patient achieved the complete resolution of skin lesions and muscular involvement, together with the stabilization of pulmonary function, as shown by lung function test (LFT) [forced vital capacity 74%; forced expiratory volume in 1 second 78%; carbon monoxide diffusion capacity (DLCO) 42%] and by HRCT, which revealed a reduction of GG areas. Blood examination demonstrated the normalization of inflammatory markers (CRP 0.24 mg/dL and ferritin 202 mg/dL). The patient continued PDN and TOF 5 mg twice a day.

Patient 2. The second case concerns a 55-year-old woman who showed up in December 2020 because of the appearance of skin lesions (Gottron's papules, mechanic's hands), severe weakness, weight loss, arthralgias, myalgias, fever, and dyspnea. Anti-MDA5 antibodies were positive, together with anti-SSA. She was initially treated with GC and methotrexate (MTX) 7.5 mg/week, discontinued because of side effects. HRCT revealed advanced fibrosis and areas of GG, coupled with global reduction in LFT. Laboratory parameters included erythrocyte sedimentation rate (ESR) 100 mm/h, CRP 1.56 mg/dL, with normal concentration of creatine kinase (CK).

The clinical evaluation demonstrated slight weakness of the legs (grade 4/5 of the Manual Muscle Test, MMT), dyschromic lesions of the arms, and alopecia. At the PDUS exam, moderate Doppler signal (grade 2-3 SMGUS), fibrosis, and focal edema were detected. Oral CYC 50 mg twice a day and PDN 75 mg/day were administered.

In February 2021, she was hospitalized because of an axillary and breast phlegmon, thus CYC was interrupted and TOF 5 mg twice a day was introduced, simultaneously to a reduction of GC dose. A second hospitalization was necessary in April due to a *Pneumocystis jirovecii* pneumonia; furthermore, elevated levels of Cytomegalovirus (CMV) were detected. The patient was successfully treated with antibiotic and antiviral therapy and TOF was suspended for 10 days.

A complete remission was achieved at the 7-month follow-up with improvements in cutaneous, muscle, and pulmonary manifestations, as well as in laboratory tests (ESR 37 mm/h, CRP 0.11 mg/dL).

In September 2021, our patient suffered from Zoster reactivation and developed a thrombophlebitis, so TOF was discontinued and only MDPN 4 mg/day was confirmed.

Patient 3. The next patient was a 75-year-old man with a past medical history of hepatitis B virus infection, atrial fibrillation, abdominal aortic aneurysm, diabetes mellitus II, depressive syndrome, and lung carcinoma.

He was hospitalized in July 2021 because of a severe iatrogenic form of arthritis, with skin and muscular involvement, whose onset dated back to the administration of checkpoint inhibitors for lung carcinoma. Patient presented a heliotrope rash and significant generalized weakness. Blood exams showed ESR 107 mm/h, CRP 14.93 mg/dL, ferritin 591 ng/mL, CK 17 UI/L. Muscle biopsy, PDUS (grade 2 SMGUS, fibroadipose degeneration), and electromyographic findings suggested the diagnosis of DM, then confirmed by positivity of anti-Mi2 antibodies too.

An oral treatment with BAR 4 mg/day and PDN 50 mg/day, gradually tapered, was set. At the 2- and 6-month follow-up, in February 2022, the patient was fully asymptomatic, and inflammatory indexes were within the normal range (ESR 2 mm/h, CRP 0.06 mg/dL, ferritin 69 ng/dL).

Considering the significant comorbidities, a different type of immunosuppression was not considered.

Patient 4. In 2019, a 63-year-old woman was diagnosed with ASS in overlap with RA. Clinically, she had dyspnea, cough, arthralgias, and mechanic's hands with anti-Jo1, anti-SSA, rheumatoid factor (RF) and anti-citrullinated protein antibodies (ACPA) positivity. She immediately underwent a cycle of RTX (2×1000 mg infusions, 2 weeks apart). Despite a maintenance treatment with mycophenolate mofetil (MMF, 2 g/day) and PDN 50 mg/day (slowly tapered to 12.5 mg/day), she experienced many flares of disease with episodes of dyspnea, fever, and an increase in muscle damage indexes (CK 605 UI/L, myoglobin 318 ng/mL).

In June 2021, HRCT and LFT demonstrated a worsening of lung involvement, while CRP and ESR were 3.95 mg/dL and 47 mm/h, respectively. Therapy was modified, increasing PDN and planning a new cycle of RTX in August.

At the 2-month follow-up, in October 2021, inflammatory indexes were still elevated, whereas pulmonary involvement was stable, but not improved. Furthermore, arthralgias worsened and ultrasound demonstrated erosions in the presence of PD signals of both hands and wrists, for which HCQ was administered.

A maintenance infusion of RTX 500 mg was planned for February 2022, 6 months from the previous infusion, and in the meanwhile therapy with BAR 4 mg/day was introduced with rapid improvement in clinical symptoms and normalization of laboratory exams. As a side effect, she suffered from mild diarrhea that did not require treatment discontinuation.

Patient 5. A 61-year-old woman with a diagnosis of seropositive RA (both ACPA and RF positivity) complicated with mild ILD, dating back to 2017, was referred to the rheumatology clinic for the appearance of skin and hand lesions and relapse of hand arthritis, despite treatment with MTX (15 mg/week) and repeated courses of oral GC. At the baseline visit, in December 2020, a typical heliotrope rash was evidenced, and hand lesions were diagnosed as mechanic's hands. The patient had a history of Raynaud's phenomenon and complained of myalgias. Ten joints were tender and six swollen. The diagnostic workup included autoimmunity and radiological examinations that documented anti-Jo1 positivity, erosions of the small joints of both hands and progression of ILD. ESR and CRP were 121 mm/h and 1.8 mg/dL, respectively. The diagnosis was then changed to ASS in overlap with RA. MTX was discontinued and RTX (2×1000 mg infusions, 2 weeks apart) plus IV-GC (3-days 125 mg pulse treatment) were administered starting in March 2021. The patient experienced an allergic reaction during the second infusion of RTX, which was immediately stopped. Maintenance therapy with MMF and oral GC was started. At the 6-month follow-up (September 2021), joint disease (6 swollen and 6 tender joints) was still active and skin lesions only partially improved. Lung involvement was stable with preserved LFT and not worsened structural disease at HRCT evaluation. Considering refractory arthritis and skin manifestations, TOF 5 mg twice a day was added to treatment and MMF was discontinued. After 3 months (December 2021), joint disease improved significantly (1 swollen joint; 5 tender joints) with a decrease in inflammatory parameters (ESR 14 mm/h, CRP 0.36 mg/dL). Simultaneously, an almost complete resolution of mechanic's hand lesions (Figure 2) and heliotrope rash was evidenced. At the following visit, in March 2022, the patient achieved complete articular and skin remission coupled with stable lung disease, allowing GC reduction, whereas TOF was continued.

Patient 6. A 26-year-old woman, with no significant past medical history, was admitted to the outpatient clinic of our rheumatology unit in May 2019 for the appearance of alopecia, skin lesions, and general malaise. She also complained of painful swelling in the wrists and small joints of the hands. A recent onset of dyspnea was also reported.

Physical examination evidenced eyelid edema, heliotrope rash, Gottron's papules on the dorsal surface of metacarpophalangeal joints and elbows, shawl sign, V-neck skin rash, digital ulcerative lesions, and arthritis of metacarpophalangeal and wrist joints. Muscle weakness, myalgias, and dysphagia were not recorded.

Laboratory parameters showed anti-MDA5 positivity, antinuclear antibodies positivity (speckled pattern at a serum dilution of 1:160 and nucleolar pattern at a serum dilution of 1:320 by indirect

immunofluorescence), RF positivity, increased ferritin level (613 ng/mL) and decreased lymphocyte count (670/ μ L). Muscle enzymes were not increased (CK level 129 U/L). CRP and ESR were normal.

LFT showed reduced DLCO to 63% of the predicted value. HRCT scan of the chest revealed extensive GG opacities with septal thickening in a “crazy paving” pattern throughout the left lung and scattered in the right lung, suggesting ILD.

Clinical, serological, and radiological findings allowed the diagnosis of anti-MDA5-associated clinically amyopathic DM (CADM) complicated by RP-ILD and therapy with 3-day course of pulse MPDN at 1000 mg/day, followed by PDN 1 mg/kg/day, intravenous CYC (every 4 weeks for 6 months, cumulative dose 5.75 g/m²) and IVIg 2 gr/kg was introduced shortly after the diagnosis in early July 2019.

Despite this approach, after 6 months, pulmonary function deteriorated rapidly along with the reoccurrence of skin lesions and joint involvement. Therefore, the patient was treated with RTX 2×1000 mg infusions within 2 weeks and maintenance therapy with MMF was introduced to allow GC tapering in January 2020.

After 4 months, HRCT showed a regression of reticulation and GG lesions. However, due to relapse of skin lesions, mainly digital ulcers and alopecia, and joint inflammation, treatment with BAR 4 mg/die was started in May 2020. Six months (November 2020) after the introduction of BAR, the patient showed a clear improvement in laboratory tests, skin and joint involvement, resolution of alopecia, and stability of ILD.

Janus kinase inhibitors

The development of JAKi has offered a new perspective in the treatment of immune-mediated disorders with the advantage of rapid onset, oral formulation, and effective steroid-sparing effect. JAKi inhibit cytokine-mediated signaling through the Janus kinase/signal transducers and activators of transcription pathway, affecting inflammatory cytokine cascade, immunoregulation, and the effect of several cellular growth factors, together with the dampening of interferon (IFN) signaling (7). The anti-inflammatory effect on skin, joint, and muscle lesions and the potential antifibrotic effects of these agents shed light on the potential efficacy of JAKi as a promising new alternative for the treatment of connective tissue diseases, especially IFN-driven disorders (8, 9). In this review, we highlight published data on the role of JAKi in IIMs, emphasizing our clinical experience on their effectiveness.

A total of 37 papers was retrieved for a total of 174 subjects treated with any JAKi: in particular, 146 subjects received TOF, 11 ruxolitinib (RUX) and 17 BAR, as reported in the supplemental content (*Supplementary Table 1*).

Tofacitinib

The first attempt employing TOF was made by Paik and Christopher-Stine in 2016 when a 55-year-old woman suffering from DM had an overall improvement in skin, joint, and muscle involvement (10). Since then and until 2021, many other papers have been published, reporting a significant amelioration or a complete resolution of skin conditions (such as rash, pruritus, ulcers, calcinosis), muscle strength, and joint involvement (8, 11-22).

Focusing on evidence from last year, we analyzed other interesting cases. Luo *et al.* described the success of TOF in healing digital ulcers and calcinotic lesions in a patient diagnosed with anti-MDA5 DM (23), whereas Castillo reported a peculiar episode of alopecia universalis responding to JAKi together with IVIg (24). A similar case is included in Plante’s review (25), in which alopecia was successfully treated with topical TOF therapy, while systemic therapy showed a good efficacy on muscle, articular and GI domains, but no benefit for a patient suffering from alopecia or for a concomitant ILD. Results from a retrospective study by Min *et al.* demonstrated the efficacy of TOF in treating muscle and skin involvement, with particular benefit on pruritus, in a cohort of 9 DM and 3 juvenile dermatomyositis (JDM) patients (26). In an open-label study, enrolling 15 new-onset, untreated adult patients with anti-MDA5-positive DM, TOF treatment

resulted in an increase in peripheral lymphocyte numbers, especially CD8+ T cells at 6 months compared with pre-treatment levels (27).

Our literature search displayed just three patients suffering from ASS and one from PM who had received TOF. The first case concerns a patient with anti-PL12 ASS-related ILD requiring mechanical ventilation and extracorporeal membrane oxygenation successfully treated with the association of GC, tacrolimus (TAC) and TOF (28). The second case concerns an unusual patient with anti-Mi2 DM that switched to anti-Jo1 positivity after a flare and developed RP-ILD (29): JAKi proved to be a winning choice, preventing the evolution of lung disease and avoiding the necessity of lung transplantation. In 2022, TOF was employed as induction therapy in an anti-EJ ASS-related ILD (30), which developed acute respiratory distress syndrome together with acute renal failure. The last case was reported by Babaoglu *et al.* and described a patient with refractory PM successfully treated with TOF, that led to an improvement of MMT scores and a complete regression of oedema at MRI after just 2 months of treatment (31).

Tofacitinib in anti-MDA5 dermatomyositis associated with rapidly progressive interstitial lung disease

Anti-MDA5 DM-associated RP-ILD deserves a special mention, due to the growing amount of evidence arising from literature. A comprehensive systematic review of this topic has been recently published by Takanashi *et al.* and includes 30 patients diagnosed with DM, as described in supplemental content (*Supplementary Table 1*) (32). TOF was employed as first-line therapy in 18 patients, as additional therapy to other immunosuppressive drugs in 10 patients with refractory disease and as re-induction therapy in two relapsing patients. Results highlight the efficacy of TOF as induction remission therapy, with 100% survival rates, and good results in refractory or relapsing cases (survival rates of 75%), although with a higher incidence of adverse events. Three deaths have been recorded, two of which caused by respiratory failure. A recent study investigated the efficacy of intensive induction therapy combining TOF, RTX and PEX in 33 severe anti-MDA5 DM patients with RP-ILD. Although two patients died, a significant improvement in survival was reported (33). Furthermore, an intriguing case series of 6 MDA5-DM with RP-ILD suggested that TOF dose escalation may be an option for MDA5-DM patients refractory to 10 mg/day of TOF and other immunosuppressants (34). Conversely, a case of anti-MDA5 CADM-ILD refractory to intensive combined immunosuppressive therapy including TOF but successfully treated with PEX has been reported, suggesting that cytokines not suppressed by TOF may still play an important role in RP-ILD (35).

After our revision work, we collected other papers about the beneficial role of TOF in patients with lung involvement (11, 23), while Fan *et al.* demonstrated TOF superiority in comparison with TAC in terms of 6-months and 1-year all-cause mortality rates (36).

Baricitinib

Evidence about the application of BAR in IIM comes from recent papers published from 2019 to 2022: it was successfully employed to treat skin lesions in adults (29 subjects) (37-40) affected by DM, showing satisfactory effects on muscle involvement too. Moreover, it proved to be effective in peculiar cases of DM, in which patients had developed alopecia areata (38), ulcerative panniculitis (39), and pruritus (41). To the best of our knowledge, no data are available about patients suffering from ASS or PM.

Ruxolitinib

The first data about RUX date back to 2014, when a 72-year-old woman suffering from DM developed a post-polycythaemia vera myelofibrosis, positive for JAK2 V617F mutation, and was treated with JAKi, which unexpectedly solved her skin and muscle symptoms (42). Later in 2018, Ladislau successfully employed RUX for 4 DM (3 anti-transcription intermediary factor 1-gamma, TIF1 γ and 1 anti-small ubiquitin-like modifier-1 activating enzyme, SAE) (43). In 2020, clinical remission was achieved by 2 women affected by DM (anti-MDA5- and anti-TIF1 γ -positive,

respectively): regarding Jalles' patient (44), a small cell carcinoma was discovered at 9 months follow-up, although not expected for this phenotype of DM, while Fetter described the effect of RUX in leading to significant hair regrowth (45). As far as we know, there are no publications about cases of ASS, IBM or PM.

Upadacitinib and Filgotinib

Up to the completion of the literature search, no data were published about the application of Filgotinib or Upadacitinib (UPA) in IIM.

Apremilast

APR is an oral inhibitor of phosphodiesterase 4 (PDE-4), currently approved for the treatment of psoriasis and psoriatic arthritis (46, 47). The blockade of PDE-4 increases cyclic adenosine monophosphate (cAMP) levels modulating cytokines expression in several cell lines (48). Increased cAMP levels result in the activation of protein kinase A that consequently inhibits certain transcription factors, such as NF- κ B, or activates others, such as cAMP responsive element binding protein, cAMP responsive element modulator, and activating transcription factor 1 (49). Such activity drives the reduction of inflammatory molecules expression, namely IFN γ , tumor necrosis factor, interleukin (IL)-12, IL-6, IL-23, IL-17, and IL-22 while increasing IL-10 levels, thus shaping the immune system through the inhibition of Th1 and Th2 responses, both implicated in IIM pathogenesis, especially in DM (50-52). APR has been successfully used to treat oral ulcers in Behçet's disease too (53). The possible shared immunological pathways, involving analogous inflammatory cascades, between skin and mucosal manifestations, across several rheumatic diseases, have paved the way for the use of APR to control recalcitrant DM.

Only four papers about the application of APR, for a total of 12 subjects, are available on PubMed. In the first paper, collecting three cases by Bitar *et al.* (54), APR was added to GC and MMF therapy in refractory cutaneous involvement of DM, leading to a decrease of unbearable scalp pruritus and an amelioration of skin disease activity and severity index. Muscle weakness improved too. A skin relapse was reported after 9 months of therapy and did not respond to any other drug employed. The impact on alopecia was not reported. Itching of the scalp with a complete resolution of pruritus and skin lesions was achieved in a patient affected by anti-TIF1 γ DM, but no notable change was observed in calcinotic lesions (55). In 2022, the results of a phase Ib clinical trial on the use of APR in DM were published by Konishi (56). Two of the five enrolled patients discontinued therapy because of diarrhea, while the remaining experienced a 40% reduction of the Cutaneous Dermatomyositis Disease Area and Severity Index (CDASI), although without experiencing any improvement in itching or skin damage index. The same year, Bitar published an open-label single-arm non-randomized controlled trial in which 8 DM with recalcitrant cutaneous manifestations were successfully treated with APR, as demonstrated by a significant decrease of CDASI (57). As far as we know, there is no evidence regarding the use of APR in the treatment of PM, JDM and ASS.

Safety issues

As expected, the most common side effect in subjects treated with JAKi was Zoster, CMV and EBV reactivation. A patient treated with TOF developed herpes simplex virus (HSV) keratitis, whereas two subjects presented orolabial HSV. Moreover, the authors described thromboembolic events, liver and hematological disorders, in addition to urinary and respiratory tract infections, both bacterial and fungal. Severe cases of infections included sepsis due to pulmonary infection and gangrenous cholecystitis.

On the other hand, and yet unsurprisingly, patients treated with APR mostly developed GI side effects, such as nausea, vomiting, and diarrhea.

Discussion and Conclusions

A growing amount of evidence about the application of small molecules in IIM has been published in the last few years, showing the potential role of these drugs in the management of subjects suffering, in particular, from refractory DM. A beneficial impact has been reported in almost every case of skin lesions, from rash to ulcers and calcinosis. Very recent data demonstrated the efficacy on the skin by an important reduction in the CDASI score. Specifically, treatment with TOF, UPA, RUX and BAR determined a decrease in CDASI by 16, 9, 20, and 11 points, respectively (58, 59). If present, muscle and joint involvement demonstrated a good response to therapy with JAKi, while it is not possible to draw any conclusion about dysphagia. Notably, data on muscle improvement are still controversial and deserve further investigation, as a good response was described in up to 94% of patients treated with JAKi but such impressive results were not confirmed in other studies (40, 60, 61).

Concerning systemic involvement, TOF could play a crucial role in intensive treatment of ILD and RP-ILD, especially in the case of anti-MDA5 positivity. Data for MDA5 patients with RP-ILD mostly come from Asian cohorts, and in 2022, it was suggested that the early use of TOF was associated with a lower risk for one-year mortality compared to TAC treatment. No increased adverse events rate was recorded for TOF (36). More studies, involving patients from Western countries are required to address epidemiological and pharmacogenomics differences and to assess the value of TOF compared to standard treatment. However, TOF stands out as a promising drug to implement the rheumatologist toolbox to face IIM management.

Less data, albeit compelling, concerns the employment of JAKi as therapy for young patients. APR may have a role when skin lesions are refractory to conventional treatment, but it has been investigated to a lesser degree than JAKi. Only few studies have addressed the possible role of APR in IIM with conflicting results. Current evidence seems to suggest that APR may improve symptoms, such as itching, with almost no effect on severe skin changes, namely calcinosis. APR can then be considered in less severe forms of DM, in which aggressive immunosuppressive therapies and high-dose GC are not required in the absence of life-threatening complications. In addition, the safety profile of APR could make this drug a viable therapeutic option in patients affected by multiple comorbidities.

Cases of ASS, IBM, and PM treated with any tsDMARD are very rare. Predictable adverse events, such as Zoster reactivation and bacterial infections, may be prevented with proper prophylaxis measures.

The analysis of only case reports and series could represent a risk of bias, as well as the lack of direct comparison with other treatment options. Nevertheless, our small cohort, as well as data coming from literature, have evidenced an overall good safety and efficacy of tsDMARDs, especially convincing for JAKi, but prospective, randomized, case-control studies are necessary in order to fully elucidate their role in the management of IIM.

References

1. Lundberg IE, Tjärnlund A, Bottai M, Werth VP, Pilkington C, Visser M de, et al. 2017 European League Against Rheumatism/American College of Rheumatology classification criteria for adult and juvenile idiopathic inflammatory myopathies and their major subgroups. *Ann Rheum Dis* 2017; 76: 1955-64.
2. Pipitone N, Salvarani C. Treatment of inflammatory myopathies. *Expert Rev Clin Immunol* 2018; 14: 607-21.
3. Pipitone N, Salvarani C. Up-to-date treatment and management of myositis. *Curr Opin Rheumatol* 2020; 32: 523-7.
4. Chiapparoli I, Galluzzo C, Salvarani C, Pipitone N. A glance into the future of myositis therapy. *Ther Adv Musculoskelet Dis* 2022; 14: 1759720X2211002.
5. Grazzini S, Rizzo C, Conticini E, D'Alessandro R, La Barbera L, D'Alessandro M, et al. The role of bDMARDs in idiopathic inflammatory myopathies: a systematic literature review. *Autoimmun Rev* 2023; 22: 103264.
6. Conticini E, Falsetti P, Al Khayyat SG, Baldi C, Bellisai F, Bardelli M, et al. A novel grey scale and Power Doppler ultrasonographic score for idiopathic inflammatory myopathies: Siena Myositis Ultrasound Grading Scale. *Rheumatology* 2021; 61: 185-94.
7. You H, Xu D, Zhao J, Li J, Wang Q, Tian X, et al. JAK inhibitors: prospects in connective tissue diseases. *Clin Rev Allergy Immunol* 2020; 59: 334-51.
8. Moghadam-Kia S, Charlton D, Aggarwal R, Oddis C V. Management of refractory cutaneous dermatomyositis: potential role of Janus kinase inhibition with tofacitinib. *Rheumatology* 2019; 58: 1011-5.
9. Li Wilkinson MG, Deakin CT, Papadopoulou C, Eleftheriou D, Wedderburn LR. JAK inhibitors: a potential treatment for JDM in the context of the role of interferon-driven pathology. *Pediatr Rheumatol Online J* 2021; 19: 146.
10. Paik JJ, Christopher-Stine L. A case of refractory dermatomyositis responsive to tofacitinib. *Semin Arthritis Rheum* 2017; 46: e19.
11. Hornig J, Weinlage T, Schmidt LH, Buerke B, Schneider U, Pavenstädt H, et al. Response of dermatomyositis with lung involvement to Janus kinase inhibitor treatment. *Z Rheumatol* 2018; 77: 952-7. [Article in German].
12. Kurtzman DJB, Wright NA, Lin J, Femia AN, Merola JF, Patel M, et al. Tofacitinib citrate for refractory cutaneous dermatomyositis: an alternative treatment. *JAMA Dermatol* 2016; 152: 944-5.
13. Wendel S, Venhoff N, Frye BC, May AM, Agarwal P, Rizzi M, et al. Successful treatment of extensive calcifications and acute pulmonary involvement in dermatomyositis with the Janus-Kinase inhibitor tofacitinib – a report of two cases. *J Autoimmun* 2019; 100: 131-6.
14. Ishikawa Y, Kasuya T, Fujiwara M, Kita Y. Tofacitinib for recurrence of antimelanoma differentiation-associated gene 5 antibody-positive clinically amyopathic dermatomyositis after remission: a case report. *Medicine* 2020; 99: e21943.
15. Ohmura S, Yamabe T, Naniwa T. Successful dose escalation of tofacitinib for refractory dermatomyositis and interstitial lung disease with anti-melanoma differentiation-associated gene 5 antibodies. *Mod Rheumatol Case Rep* 2021; 5: 76-81.
16. Navarro-Navarro I, Jiménez-Gallo D, Rodríguez-Mateos ME, Rodríguez-Hernández C, Linares-Barríos M. Treatment of refractory anti-NXP2 and anti-TIF1 γ dermatomyositis with tofacitinib. *J Dtsch Dermatol Ges* 2021; 19: 443-7.
17. Crespo Cruz A, del Boz J, Romero Gómez C. Good response to tofacitinib in refractory amyopathic dermatomyositis. *Actas Dermosifiliogr* 2021; 112: 374-6.
18. Hosokawa Y, Oiwa H. A case of refractory interstitial lung disease in anti-MDA5-positive dermatomyositis that improved after switching to tofacitinib. *J Clin Rheumatol* 2021; 27: S661-2.

19. Shneyderman M, Ahlawat S, Christopher-Stine L, Paik JJ. Calcinosis in refractory dermatomyositis improves with tofacitinib monotherapy: a case series. *Rheumatology* 2021; 60: e387-8.
20. Paik JJ, Casciola-Rosen L, Shin JY, Albayda J, Tiniakou E, Leung DG, et al. Study of tofacitinib in refractory dermatomyositis: an open-label pilot study of ten patients. *Arthritis Rheumatol* 2021; 73: 858-65.
21. Paik JJ, Shneyderman M, Gutierrez-Alamillo L, Albayda J, Tiniakou E, Perin J, et al. Long-term extension study of tofacitinib in refractory dermatomyositis. *Arthritis Rheumatol* 2022; 74: 371-2.
22. Robert M, Gallay L, Garnier L, Pescarmona R, Hot A. Contribution of the interferon score in the management of an anti-NXP2 dermatomyositis patient with calcinosis successfully treated with tofacitinib. *Joint Bone Spine* 2023; 90: 105532.
23. Luo M, Chen L, He H, He F. Treatment of MDA5-positive dermatomyositis complicated by gangrenous cholecystitis with tofacitinib. *Eur J Med Res* 2022; 27: 68.
24. Castillo R, Albayda J. Refractory alopecia universalis associated with dermatomyositis successfully treated with tofacitinib. *Mod Rheumatol Case Rep* 2022; 6: 199-202.
25. Plante J, Eason C, Santa Lucia G, Robinson I, Elston D. A retrospective review of tofacitinib in the treatment of refractory dermatomyositis. *J Drugs Dermatol* 2022; 21: 1133-4.
26. Min MS, Alsarheed A, Kassamali B, Mazori DR, Schaefer M, Merola JF, et al. Tofacitinib as treatment for refractory dermatomyositis: a retrospective study from 2 academic medical centers. *J Am Acad Dermatol* 2022; 86: 423-5.
27. Wang Y, Luo J, Lv X, Li Y, An Q, Mo L, et al. Tofacitinib for new-onset adult patients with anti-melanoma differentiation-associated 5 gene antibody positive dermatomyositis. *Clin Rheumatol* 2023; 42: 1847-53.
28. Pineton De Chambrun M, Hervier B, Chauveau S, Tandjaoui-Lambiotte Y, Combes A, Uzunhan Y. Tofacitinib in antisynthetase syndrome-related rapidly progressive interstitial lung disease. *Rheumatology* 2020; 59: e142-3.
29. Conca W, Weheba I, Abouzied ME, Abdelsayed A, Aleyouni Y, Al-Mutairy E, et al. Iacta Alea Est: the inexorable advance of tofacitinib in the treatment of dermatomyositis-associated rapidly progressive interstitial lung disease. A case report. *Front Pharmacol* 2020; 11: 585761.
30. Tseng C-W. Tofacitinib treatment in anti-glycyl-tRNA synthetase antibody interstitial lung disease – a case report. *Int J Rheum Dis* 2023; 26: 781-5.
31. Babaoglu H, Varan O, Atas N, Satis H, Salman R, Tufan A. Tofacitinib for the treatment of refractory polymyositis. *J Clin Rheumatol* 2019; 25: e141-2.
32. Takanashi S, Kaneko Y, Takeuchi T. Tofacitinib in interstitial lung disease complicated with anti-MDA5 antibody-positive dermatomyositis: a literature review. *Mod Rheumatol* 2021; 32: 231-7.
33. Shirai T, Machiyama T, Sato H, Ishii T, Fujii H. Intensive induction therapy combining tofacitinib, rituximab and plasma exchange in severe anti-melanoma differentiation-associated protein-5 antibody-positive dermatomyositis. *Clin Exp Rheumatol* 2023; 41: 291-300.
34. Ida T, Furuta S, Takayama A, Tamura J, Hayashi Y, Abe K, et al. Efficacy and safety of dose escalation of tofacitinib in refractory anti-MDA5 antibody-positive dermatomyositis. *RMD Open* 2023; 9: e002795.
35. Hiraoka D, Ishizaki J, Horie K, Matsumoto T, Suemori K, Takenaka K, et al. A case of clinically amyopathic dermatomyositis that was refractory to intensive immunosuppressive therapy including tofacitinib, but successfully treated with plasma exchange therapy. *Mod Rheumatol Case Rep* 2022; 6: 194-8.
36. Fan L, Lyu W, Liu H, Jiang H, Chen L, Liu Y, et al. A retrospective analysis of outcome in melanoma differentiation-associated gene 5-related interstitial lung disease treated with tofacitinib or tacrolimus. *J Rheumatol* 2022; 49: 1356-64.

37. Delvino P, Bartoletti A, Monti S, Biglia A, Montecucco C, Carducci M, et al. Successful treatment with baricitinib in a patient with refractory cutaneous dermatomyositis. *Rheumatology* 2020; 59: e125-7.
38. Chen D, Huang W, Zhongjie W, Feifeng R, Luo L, Jun Z, et al. Good efficacy achieved by baricitinib in the treatment of anti-MDA5 antibody-positive dermatomyositis with alopecia areata. *Rheumatology* 2022;61: e221-3.
39. Fischer K, Aringer M, Steininger J, Heil J, Beissert S, Abraham S, et al. Improvement of cutaneous inflammation and panniculitis in patients with dermatomyositis by the Janus kinase inhibitor baricitinib. *Br J Dermatol* 2022; 187: 432-5.
40. Landon-Cardinal O, Guillaume-Jugnot P, Toquet S, Sbeih N, Rigolet A, Champtiaux N, et al. JAK inhibitors for the treatment of adult dermatomyositis: a pilot study. *J Am Acad Dermatol* 2023; 88: 924-6.
41. Zhao Q, Zhu Z, Fu Q, Shih Y, Wu D, Chen L, et al. Baricitinib for the treatment of cutaneous dermatomyositis: a prospective, open-label study. *J Am Acad Dermatol* 2022; 87: 1374-6.
42. Hornung T, Janzen V, Heidgen F-J, Wolf D, Bieber T, Wenzel J. Remission of recalcitrant dermatomyositis treated with ruxolitinib. *N Engl J Med* 2014; 371: 2537-8.
43. Ladislau L, Suárez-Calvet X, Toquet S, Landon-Cardinal O, Amelin D, Depp M, et al. JAK inhibitor improves type I interferon induced damage: proof of concept in dermatomyositis. *Brain* 2018; 141: 1609-21.
44. Jalles C, Deroux A, Tardieu M, Lugosi M, Viel S, Benveniste O, et al. Severe MDA5 dermatomyositis associated with cancer and controlled by JAK inhibitor. *Rev Med Interne* 2020; 41: 421-4.
45. Fetter T, Cuevas Rios G, Niebel D, Bieber T, Wenzel J. Unexpected hair regrowth in a patient with longstanding alopecia universalis during treatment of recalcitrant dermatomyositis with the Janus kinase inhibitor ruxolitinib. *Acta Derm Venereol* 2020; 100: adv00144.
46. Paul C, Cather J, Gooderham M, Poulin Y, Mrowietz U, Ferrandiz C, et al. Efficacy and safety of apremilast, an oral phosphodiesterase 4 inhibitor, in patients with moderate-to-severe plaque psoriasis over 52 weeks: a phase III, randomized controlled trial (ESTEEM 2). *Br J Dermatol* 2015; 173: 1387-99.
47. Edwards CJ, Blanco FJ, Crowley J, Birbara CA, Jaworski J, Aelion J, et al. Apremilast, an oral phosphodiesterase 4 inhibitor, in patients with psoriatic arthritis and current skin involvement: a phase III, randomised, controlled trial (PALACE 3). *Ann Rheum Dis* 2016; 75: 1065-73.
48. Keating GM. Apremilast: a review in psoriasis and psoriatic arthritis. *Drugs* 2017; 77: 459-72.
49. Schafer P. Apremilast mechanism of action and application to psoriasis and psoriatic arthritis. *Biochem Pharmacol* 2012; 83: 1583-90.
50. Notarnicola A, Lapadula G, Natuzzi D, Lundberg IE, Iannone F. Correlation between serum levels of IL-15 and IL-17 in patients with idiopathic inflammatory myopathies. *Scand J Rheumatol* 2015; 44: 224-8.
51. Hassan AB, Fathi M, Dastmalchi M, Lundberg IE, Padyukov L. Genetically determined imbalance between serum levels of tumour necrosis factor (TNF) and interleukin (IL)-10 is associated with anti-Jo-1 and anti-Ro52 autoantibodies in patients with poly- and dermatomyositis. *J Autoimmun* 2006; 27: 62-8.
52. Cerezo LA, Vencovský J, Šenolt L. Cytokines and inflammatory mediators as promising markers of polymyositis/dermatomyositis. *Curr Opin Rheumatol* 2020; 32: 534-41.
53. Hatemi G, Mahr A, Ishigatsubo Y, Song Y-W, Takeno M, Kim D, et al. Trial of apremilast for oral ulcers in Behçet's syndrome. *N Engl J Med* 2019; 381: 1918-28.
54. Bitar C, Maghfour J, Ho-Pham H, Stumpf B, Boh E. Apremilast as a potential treatment for moderate to severe dermatomyositis: a retrospective study of 3 patients. *JAAD Case Rep* 2019; 5: 191-4.

55. Charlton D, Moghadam-Kia S, Smith K, Aggarwal R, English JC, Oddis C V. Refractory cutaneous dermatomyositis with severe scalp pruritus responsive to apremilast. *J Clin Rheumatol* 2021; 27: S561-2.
56. Konishi R, Tanaka R, Inoue S, Ichimura Y, Nomura T, Okiyama N. Evaluation of apremilast, an oral phosphodiesterase 4 inhibitor, for refractory cutaneous dermatomyositis: a phase 1b clinical trial. *J Dermatol* 2022; 49: 118-23.
57. Bitar C, Ninh T, Brag K, Foutouhi S, Radosta S, Meyers J, et al. Apremilast in recalcitrant cutaneous dermatomyositis: a nonrandomized controlled trial. *JAMA Dermatol* 2022; 158: 1357-66.
58. Ma C, Liu M, Cheng Y, Wang X, Zhao Y, Wang K, et al. Therapeutic efficacy and safety of JAK inhibitors in treating polymyositis/dermatomyositis: a single-arm systemic meta-analysis. *Front Immunol* 2024; 15: 1382728.
59. Beckett M, Dutz J, Huang K. Upadacitinib therapy in refractory inflammatory myositis: a case series of 10 patients. *RMD Open* 2024; 10: e003837.
60. Beckett M, Tan J, Bonnardeaux E, Dutz J, Shojania K, To F, et al. Tofacitinib therapy in refractory inflammatory myositis: a retrospective cohort study of 41 patients. *Rheumatology* 2024; 63: 1432-6.
61. Paik JJ, Lubin G, Gromatzky A, Mudd PN, Ponda MP, Christopher-Stine L. Use of Janus kinase inhibitors in dermatomyositis: a systematic literature review. *Clin Exp Rheumatol* 2023; 41: 348-58.

Online supplementary material

Supplementary Table 1. Supplemental demographic and clinical data of patients treated with targeted synthetic disease modifying anti-rheumatic drugs.

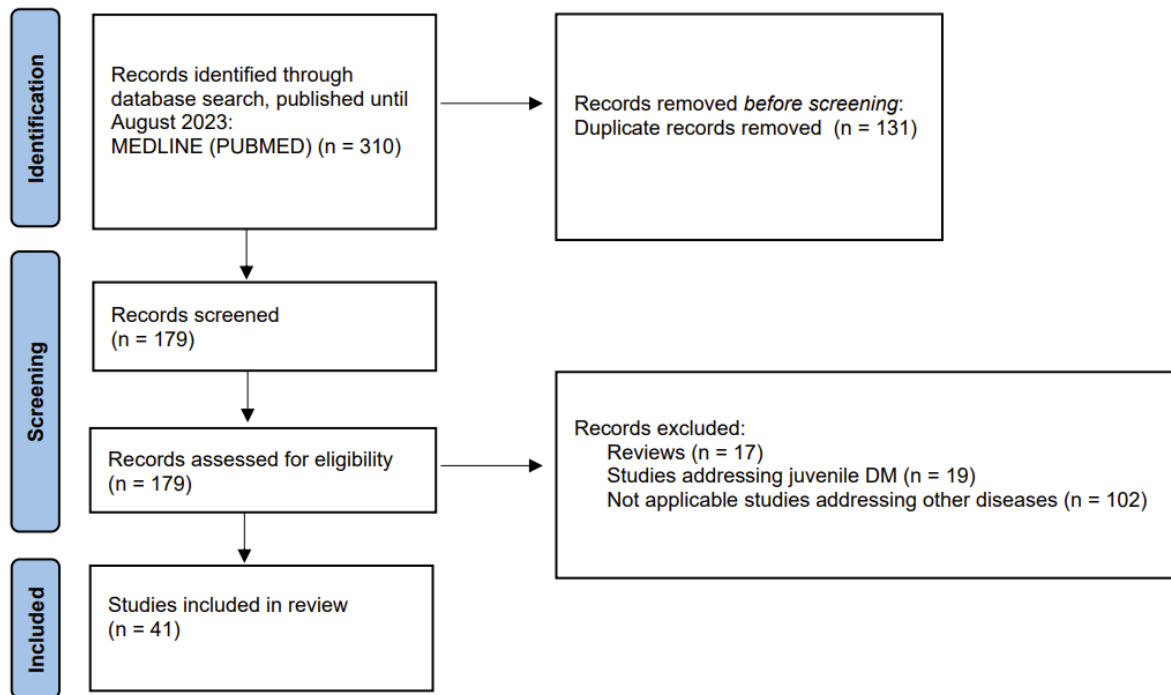


Figure 1. Preferred Reporting Items for Systematic Reviews and Meta-Analyses flowchart of study selection.

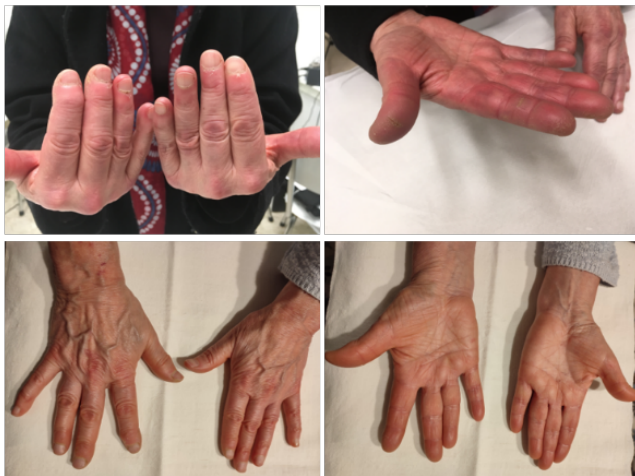

Figure 2. Patient 5: antisynthetase syndrome/AR, typical mechanic's hands before (upper part of the figure) and after treatment with tofacitinib (lower part of the figure).