

Ultrasound assessment of Achilles enthesitis: a dedicated training program

G. Smerilli¹, E. Cipolletta¹, G.M. Destro Castaniti², G. Pieroni¹, G. Sartini¹, A. Cenci¹, A. Di Matteo¹, M. Di Carlo¹, G. Guggino², W. Grassi¹, E. Filippucci¹

¹Rheumatology Unit, Department of Clinical and Molecular Sciences, Polytechnic University of Marche, "Carlo Urbani" Hospital, Jesi, Ancona, Italy;

²Rheumatology Section, Department of Health Promotion, Mother and Child Care, Internal Medicine and Medical Specialties, University of Palermo, "P. Giaccone" Hospital, Palermo, Italy

SUMMARY

Objective. To describe an intensive and multimodal ultrasound (US) training program focused on Achilles enthesitis and to illustrate the learning curve of trainees without experience.

Methods. Three medical students (trainees) and two rheumatologists experienced in musculoskeletal US (trainers) were involved in the training program, which encompassed one preliminary theoretical-practical meeting and five scanning sessions (two patients per session). The students and one expert performed the US examination of the Achilles enthesis bilaterally. The trainees acquired representative images and assessed the presence of Outcome Measures in Rheumatology (OMERACT) US abnormalities of enthesitis. The experts provided feedback addressing trainees' misinterpretations, and the quality of the acquired images was evaluated. A dedicated questionnaire was used to evaluate the students' confidence. After each session, five sets of static images (total=100 images of most commonly scanned entheses) were provided and scored by the students according to OMERACT US definitions. Total agreement and prevalence and bias adjusted kappa (PABAK) were used to evaluate the concordance between the trainees and the expert sonographer.

Results. The total agreement and PABAK significantly improved between the first and fifth scanning sessions (76.2% versus 92.9%, $p<0.01$, and 0.5 versus 0.79, $p<0.01$) and between the first and fifth static image sets (64.5% versus 81.9%, $p<0.01$, and 0.29 versus 0.74, $p<0.01$). Image quality did not significantly improve ($p=0.34$). A significant increase in trainees' confidence was registered ($p<0.01$).

Conclusions. The described training program rapidly improved the students' performance in the US assessment of Achilles enthesitis, appearing to be an effective starting model for the future development of pathology-oriented teaching programs for the US in rheumatology.

Key words: Psoriatic arthritis, ultrasonography, learning curve, tendinopathy.

Reumatismo, 2024; 76 (4): 243-250

INTRODUCTION

Enthesitis is a major feature of seronegative spondyloarthritis (SpA) and psoriatic arthritis (PsA). It is part of the Classification for Psoriatic Arthritis criteria (1), and the Assessment of Spondyloarthritis International Society classification criteria for axial and peripheral SpA (2). Moreover, enthesitis has relevant therapeutic implications according to the Group for Research and Assessment of Psoriasis and Psoriatic Arthritis (3), and the European League Against Rheumatism (EULAR) recommendations for the management of PsA (4).

Ultrasound (US) offers an accurate assessment of several morphostructural and vascular abnormalities indicative of enthesal pathology, being a reliable, cost-effective, and non-invasive imaging technique to use on top of clinical examination (5-9).

The Outcome Measure in Rheumatology (OMERACT) US Task Force agreed on the following abnormalities to be considered part of the spectrum of enthesitis in SpA: power Doppler (PD) signal (≤ 2 mm from the cortical bone), hypoechogenicity and thickening as inflammatory components; calcification/enthesophyte and bone erosions as structural components (10).

Corresponding author
Gianluca Smerilli
Rheumatology Unit,
Department of Clinical and
Molecular Sciences, Polytechnic
University of Marche,
"Carlo Urbani" Hospital
Jesi, Ancona, Italy
E-mail: smerilli.gianluca@gmail.com

Despite such premises, US is not routinely used by rheumatologists for the assessment of enthesal pathology, and, in addition to logistic and time issues, this may be partially due to its operator dependency and the consequent need for a supervised training program.

To date, several US teaching experiences in rheumatology have been described (11-16), but a dedicated theoretical-practical teaching program focusing on the enthesis has not been proposed yet.

The aims of this study were to describe an intensive and multimodal (*i.e.*, composed of theory fundamentals, static image evaluations, and supervised 'hands-on' sessions with patients) training program focused on Achilles enthesitis and to illustrate the learning curve of trainees without any experience in musculoskeletal US.

■ MATERIALS AND METHODS

Study design

Three medical students with an interest in rheumatology and no experience in US took part in the study as trainees. Two rheumatologists with 4 years (G.Sm.) and >20 years (E.F.) of experience in musculoskeletal US took part in the study as trainers. The training program was articulated throughout one preliminary meeting and five live scanning sessions (in 5 nonconsecutive days, lasting at least 4 hours per day) over the course of 2 months.

The study was conducted in accordance with the Helsinki Declaration and was approved by the local ethics committee (Comitato Etico Regione Marche, ID: 1996). All patients signed a written informed consent.

Preliminary meeting

During the preliminary meeting, the trainees were provided with a core set of scientific articles describing both the standard scanning technique of Achilles tendon and enthesis and the key US findings of enthesitis (7, 10, 17-20).

A brief lesson (~30 minutes) on the sonographic semiotics of enthesitis was made by the expert sonographer (E.F.), showing and describing a set of 20 previously acquired US images.

Then, the trainees and the trainers moved to the US examination room, where the fundamentals of the functioning of the US machine were explained (*e.g.*, probe positioning, knobology, artifacts, PD mode use). Afterwards, the students performed under the guidance of the experts a US assessment of the Achilles enthesis of two healthy volunteers.

Live scanning sessions

Patients

Two patients were evaluated in each live scanning session (10 patients in total). The patients to be enrolled were previously selected by another rheumatologist with 5 years of experience in musculoskeletal US (E.C.) and were affected by PsA (n=8) and calcium pyrophosphate deposition disease (n=2).

Ultrasound assessment - acquisition

US examinations were performed using a MyLab Class C (Esaote, Genoa, Italy), equipped with a broadband 6-18 MHz linear probe. PD settings were pre-defined with a pulse repetition frequency of 750 Hz and a frequency of 9.1 MHz. The gain was set to the highest value, not generating artifacts under the bony cortex.

First, one of the experts (G.Sm.) and then the trainees independently performed the bilateral US examinations of Achilles enthesis in each patient. The trainees could not observe other trainees' scanning. The patients were lying prone with their feet hanging out of the examination table in a neutral position. US examinations were carried out using a multiplanar scanning technique, and particular attention was paid to avoiding excessive pressure with the transducer.

While the trainees were performing the exam, the expert supervised (without talking to the students) and took note of the scanning mistakes to be discussed at the end of the session with all the participants. The trainees were asked to acquire one greyscale (GS) and one PD image for each scanned enthesis. The time needed to complete each bilateral US examination was recorded.

Ultrasound assessment - interpretation

According to the OMERACT definitions, each sonographer was asked to identify the presence or absence of the following US elementary lesions: enthesal hypoechoogenicity, enthesal thickening, PD signal <2 mm from the bony cortex, calcification/enthesophyte, and enthesal bone erosion (10).

Image quality assessment

At the end of each live scanning session, one of the expert sonographers (E.F.) scored the images acquired by the trainees (one GS image and one PD image per enthesis) from 0 (the lowest quality) to 10 (the highest quality). The expert sonographer motivated the score according to a pre-defined set of parameters of image quality. Such parameters were: good depiction of bone profile and tendon margins, image centered on the enthesis, absence of artifacts on PD images, appropriate depth, and focus positioning. After discussing the scores with the trainees, the expert explained how to improve the quality of the US images.

Sonographer Reported Outcome

At the end of each examination, the Sonographer Reported Outcome questionnaire was given to each trainee to evaluate the subjective confidence in the acquisition and interpretation of US images (Table 1).

Static images

The day after each live session, a set of 20 static images (100 images in total) was pro-

vided to the trainees. The images had good quality and resolution, with calipers if needed (*i.e.*, for the understanding of the distance between PD and the cortical bone). They were representative of the whole spectrum of enthesal abnormalities and had been acquired in 70 patients with SpA at the level of the most commonly assessed entheses (*i.e.*, lateral epicondyle, quadriceps tendon insertion on the upper pole of the patella, proximal and distal patellar tendon entheses, Achilles tendon entheses).

The expert sonographers involved in the study established by consensus the presence/absence of each elementary component of US enthesitis in all images.

The participants were asked to score as present/absent each elementary component included in the 2018 OMERACT definition of US enthesitis in SpA and PsA (10), as they did during the previous live scanning sessions.

Statistical analysis

Results are expressed as mean and standard deviation for quantitative variables with a normal distribution, and as number and/or percentage for qualitative variables. The U Mann-Whitney test was used to compare quantitative variables and the Chi-square test for qualitative variables.

Unweighted total agreement and unweighted prevalence and bias adjusted kappa (PABAK) were employed to evaluate the concordance between beginners and the expert sonogra-

Table 1 - Sonographer Reported Outcome questionnaire.

	NRS 0-10
Question 1. How confident do you feel in the US assessment (acquisition + interpretation) of enthesitis?	
Question 2. How confident do you feel in the acquisition of US images of enthesitis?	
Question 3. How confident do you feel in the interpretation of US images of enthesitis?	
Question 4.1. Please score from 0 to 10 the quality of the last US images of the Achilles enthesis you acquired (right Achilles, greyscale)	
Question 4.2. Please score from 0 to 10 the quality of the last US images of the Achilles enthesis you acquired (right Achilles, Doppler)	
Question 4.3. Please score from 0 to 10 the quality of the last US images of the Achilles enthesis you acquired (left Achilles, greyscale)	
Question 4.4. Please score from 0 to 10 the quality of the last US images of the Achilles enthesis you acquired (left Achilles, Doppler)	

NRS, numerical rating scale; US, ultrasound.

pher. Kappa coefficients were interpreted according to Landis and Koch (21).

We tested the trend for sonographers' improvement over time (*i.e.*, the score given by the expert and the Sonographer Reported Outcome) with the Jonckheere-Terpstra test. P values <0.05 were considered significant. Statistical analysis was performed using Statistical Package for Social Sciences (SPSS), version 26.0 (IBM, Armonk, NY, USA).

■ RESULTS

Live scanning session - agreement

The total agreement between the trainees and the expert sonographer in the identification of US abnormalities of enthesitis sig-

nificantly improved during the training program, with a significant difference between the first and the fifth scanning session (76.2% versus 92.9%, $p < 0.01$) (Figure 1A). The PABAK as well showed an improvement in the agreement between the first and the fifth live session (0.50 versus 0.79, $p < 0.01$).

Live scanning session - image quality

In order to evaluate the improvement in the acquisition of the images, the average of the scores given by the expert to each trainee at the end of every scanning session was calculated (*Supplementary Table 1*). While a trend of improvement in image quality was recorded, a statistically significant difference between the first and fifth sessions was not reached (5.25 versus 5.88, $p = 0.34$), Trainee 1 reached an average score ≥ 6 in the third and fifth sessions, Trainee 3 reached an average score ≥ 6 in the fourth session, while Trainee 2 never reached an average score ≥ 6 . Examples of images acquired during the first and fifth scanning sessions by the three trainees are shown in Figure 2.

Live scanning session - time

The average time needed to complete the bilateral US examination decreased from the first to the fifth session: 13.3 ± 5.2 minutes versus 8.7 ± 2.4 minutes (34% reduction) without reaching statistical significance ($p = 0.12$).

Sonographer Reported Outcome

The Sonographer Reported Outcome questionnaire showed an improvement in the subjective confidence of the trainees throughout the teaching program (*Supplementary Table 2*). In particular, a statistically significant improvement was noted in each question between the first and the fifth scanning session ($p < 0.01$).

Static images

The total agreement between the trainees and the evaluation made by the expert sonographers in the identification of US abnormalities of enthesitis on static images significantly improved during the training program, with a significant difference be-

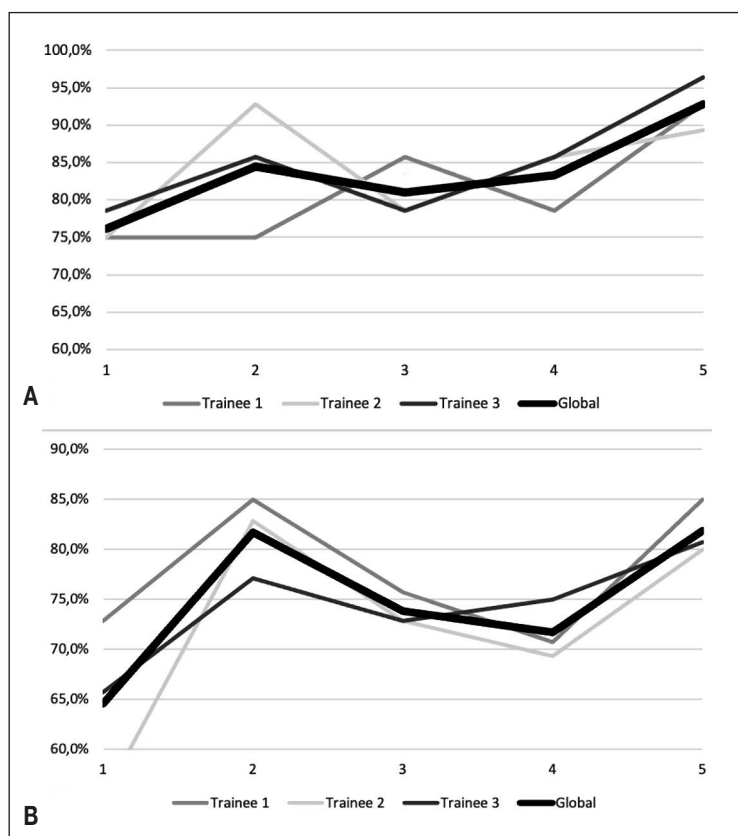


Figure 1 - A) Total agreement on hands-on session between the trainees and the expert sonographer (Trainee 1, Trainee 2, Trainee 3 and global agreement of the three trainees) in the identification of the US abnormalities of enthesitis; B) total agreement on static images between the trainees and the evaluation made by the experts (Trainee 1, Trainee 2, Trainee 3 and global agreement of the three trainees) in the identification of the US abnormalities of enthesitis.

tween the first and the fifth images set (64.5% versus 81.9%, $p < 0.01$) (Figure 1B). The PABAK also showed an improvement in the agreement between the first and the fifth live session (0.29 versus 0.74, $p < 0.01$).

Discussion and Conclusions

Interest is growing in the role of US in the assessment of enthesitis in SpA (22-28). Indeed, the clinical identification of enthesal pathology may be challenging (29-33) while other imaging modalities such as conventional radiography and magnetic resonance imaging present several limitations (19).

Thus, US has the potential to be the first-line method in the assessment of enthesitis and the basic knowledge required to acquire and interpret enthesal US images should be ideally part of the skill set of each rheumatologist (7).

However, US is an operator-dependent tool, and this implies the need for adequate and standardized training.

The best US teaching program may vary according to the pathology and/or the region of interest and, at the same time, to the background knowledge and experience of the trainee. As far as we know, a dedicated theoretical-practical teaching program for operators without experience in the US assessment of enthesitis has not been previously described.

With the aim to standardize the teaching of musculoskeletal US in rheumatology, recommendations for the content and conduct of EULAR musculoskeletal US courses were developed in 2007 (34). It was emphasized that 50-60% of total time should be spent in practical training, while 40-50% of total time should be spent in theoretical teaching. The EULAR musculoskeletal US course, articulated in three levels (~20 hours each), provides a well-rounded and comprehensive curriculum encompassing the whole spectrum of pathology as well as research aspects, technical innovations, pediatric rheumatology, and US-guided procedures (34).

In parallel, disease-oriented intensive training programs have been proposed and can be considered complementary to the EU-

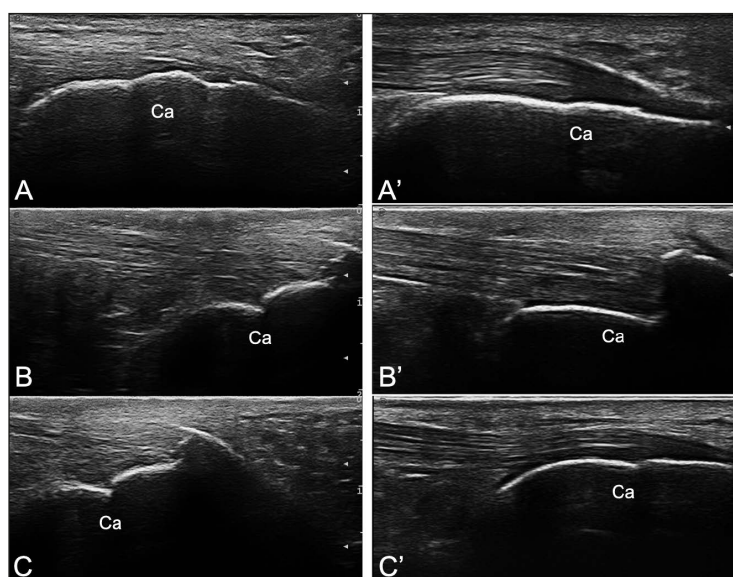


Figure 2 - Longitudinal scans of the Achilles enthesis acquired with a 6-18 MHz linear probe by the three trainees during the first (A, B, C) and the fifth (A', B', C') live session. A clearer depiction of the bone profile and tendon margins can be appreciated in A', B' and C' compared to A, B, C. Ca, calcaneal bone.

LAR musculoskeletal US course, offering further insight and specific competencies in a specific area of interest.

For example, Gutierrez *et al.* demonstrated that after a 1-week disease-oriented training program, rheumatologists with limited experience in US were satisfactorily able to detect and interpret the main US signs indicative of monosodium urate crystal deposits in different tissues in patients with gout (13).

Thus, we aimed to describe an intensive and multimodal (*i.e.*, composed of theory fundamentals, static image evaluations, and supervised 'hands-on' sessions with patients) training program focused on the Achilles enthesis and to illustrate the learning curve of trainees without any experience in musculoskeletal US. Our results showed that the proposed training program was effective, with a significant improvement in the concordance between the students and the expert sonographer, reaching a total agreement of 92.9% and a substantial PABAK (0.79). Such improvement in the identification of US enthesal pathology at the Achilles enthesis was mirrored by a similar improvement in the scoring of static

images according to the OMERACT definitions of enthesitis.

On the other side, the quality of acquired US images did not significantly improve. This may be explained by the fact that the trainees had no previous experience in US and highlights how distinct skills are involved in the learning process of the acquisition compared to the interpretation of US images. A longer observation period and a higher number of trainees are required to draw more definite conclusions. The lack of improvement in the quality of the images is an obstacle to the implementation of pure “interpretative” skills (*i.e.*, scoring pathology of static images) in real life. Nevertheless, we believe that the relationship between the improvement of image quality, interpretative skills, the self-confidence of the trainee, and the time consumed to complete the examination should be taken into account for the future development of US teaching programs in rheumatology. The main limitation of the present study was represented by the small number of trainees involved. Moreover, the number of patients included in the live scanning sessions could not guarantee a sufficient variability of scenarios to cover the entire spectrum of enthesal pathology. Finally, a separate analysis of the learning curve of the different US abnormalities could not be made due to the small sample size. However, even if it is likely that some findings could be more easily recognizable (*i.e.*, enthesophytes and PD signal), further research is needed to confirm such a hypothesis. In conclusion, even if the learning curve in musculoskeletal US is generally perceived as ‘endless’, the present study demonstrated that the described training program rapidly improved the trainees’ performance on both live scanning sessions and static US image evaluation. This intensive and multimodal approach can be considered a model for the future development of pathology-oriented teaching programs for US in rheumatology.

Contributions

GSm, EF, designed the study; EC, carried out the statistical analysis; GSm, wrote the manuscript; GSm, EC, GMDC, GP, GSa,

ADM, MDC, GG, WG, EF, contributed to the acquisition and interpretation of the data. All the authors revised the manuscript critically and approved the final version to be published.

Conflict of interest

EF has received speaking fees from AbbVie, Amgen, Bristol-Myers Squibb, Janssen-Cilag, Lilly, Novartis, Pfizer, Roche and Union Chimique Belge Pharma. WG has received speaking fees from AbbVie, Celgene, Grünenthal, Pfizer and Union Chimique Belge Pharma. All the other authors disclose no conflict of interest.

Ethics approval and consent to participate

This study was approved by the local ethics committee (Comitato Etico Regione Marche, ID:1996).

Informed consent

All patients signed a written informed consent.

Funding

No specific funding was received from any bodies in the public, commercial or not-for-profit sectors to carry out the work described in this article.

Availability of data and materials

Data and materials are available from the corresponding author upon request.

REFERENCES

1. Taylor W, Gladman D, Helliwell P, Marchesoni A, Mease P, Mielants H. Classification criteria for psoriatic arthritis: development of new criteria from a large international study. *Arthritis Rheum.* 2006; 54: 2665-73.
2. Rudwaleit M, van der Heijde D, Landewé R, Akkoc N, Brandt J, Chou CT, et al. The Assessment of SpondyloArthritis International Society classification criteria for peripheral spondyloarthritis and for spondyloarthritis in general. *Ann Rheum Dis.* 2011; 70: 25-31.
3. Coates LC, Kavanaugh A, Mease PJ, Soriano ER, Acosta-Felquer ML, Armstrong AW, et al. Group for Research and Assessment of Psoriasis and Psoriatic Arthritis 2015 treatment recommendations for psoriatic arthritis. *Arthritis Rheumatol.* 2016; 68: 1060-71.

4. Gossec L, Baraliakos X, Kerschbaumer A, de Wit M, McInnes I, Dougados M, et al. EULAR recommendations for the management of psoriatic arthritis with pharmacological therapies: 2019 update. *Ann Rheum Dis*. 2020; 79: 700-12.
5. Bruyn GA, Iagnocco A, Naredo E, Balint PV, Gutierrez M, Hammer HB, et al. OMERACT definitions for ultrasonographic pathologies and elementary lesions of rheumatic disorders 15 years on. *J Rheumatol*. 2019; 46: 1388-93.
6. Tom S, Zhong Y, Cook R, Aydin SZ, Kaeley G, Eder L, et al. Development of a preliminary ultrasonographic enthesitis score in psoriatic arthritis - GRAPPA ultrasound working group. *J Rheumatol*. 2019; 46: 384-90.
7. Smerilli G, Di Matteo A, Cipolletta E, Grassi W, Filippucci E. Enthesitis in psoriatic arthritis, the sonographic perspective. *Curr Rheumatol Rep*. 2021; 23: 75.
8. Smerilli G, Cipolletta E, Di Carlo M, Di Matteo A, Grassi W, Filippucci E. Power doppler ultrasound assessment of A1 pulley. A new target of inflammation in psoriatic arthritis? *Front Med*. 2020; 7: 204.
9. Molina Collada J, Macía-Villa C, Plasencia C, Álvaro-Gracia JM, de Miguel E. Doppler enthesitis: a potential useful outcome in the assessment of axial spondyloarthritis and psoriatic arthritis. *Clin Rheumatol*. 2021; 40: 2013-20.
10. Balint PV, Terslev L, Aegerter P, Bruyn GAW, Chary-Valckenaere I, Gandjbakhch F, et al. Reliability of a consensus-based ultrasound definition and scoring for enthesitis in spondyloarthritis and psoriatic arthritis: an OMERACT US initiative. *Ann Rheum Dis*. 2018; 77: 1730-5.
11. Filippucci E, Unlu Z, Farina A, Grassi W. Sonographic training in rheumatology: a self teaching approach. *Ann Rheum Dis*. 2003; 62: 565-7.
12. Taggart A, Filippucci E, Wright G, Bell A, Cairns A, Meenagh G, et al. Musculoskeletal ultrasound training in rheumatology: the Belfast experience. *Rheumatology*. 2006; 45: 102-5.
13. Gutiérrez M, Di Geso L, Rovisco J, Di Carlo M, Ariani A, Filippucci E, et al. Ultrasound learning curve in gout: a disease-oriented training program. *Arthritis Care Res*. 2013; 65: 1265-74.
14. Torralba KD, Cannella AC, Kissin EY, Bolster MB, Salto LM, Higgs J, et al. Musculoskeletal ultrasound instruction in adult rheumatology fellowship programs. *Arthritis Care Res*. 2020; 72: 859-70.
15. Miguel C, De Miguel E, Batlle-Gualda E, Rejón E, Lojo L. Teaching enthesitis ultrasound: experience of an ultrasound training workshop. *Rheumatol Int*. 2012; 32: 4047-52.
16. Zengin O, Onder ME. Educational quality of YouTube videos on musculoskeletal ultrasound. *Clin Rheumatol*. 2021; 40: 4243-51.
17. Terslev L, Naredo E, Iagnocco A, Balint PV, Wakefield RJ, Aegerter P, et al. Defining enthesitis in spondyloarthritis by ultrasound: results of a Delphi process and of a reliability reading exercise. *Arthritis Care Res*. 2014; 66: 741-8.
18. Möller I, Janta I, Backhaus M, Ohrndorf S, Bong DA, Martinoli C, et al. The 2017 EULAR standardised procedures for ultrasound imaging in rheumatology. *Ann Rheum Dis*. 2017; 76: 1974-9.
19. Kaeley GS. Enthesitis in psoriatic arthritis (Part 2): imaging. *Rheumatology*. 2020; 59: i15-20.
20. Filippucci E, Aydin SZ, Karadag O, Salaffi F, Gutierrez M, Direskeneli H, et al. Reliability of high-resolution ultrasonography in the assessment of Achilles tendon enthesopathy in seronegative spondyloarthropathies. *Ann Rheum Dis*. 2009; 68: 1850-5.
21. Landis JR, Koch GG. The measurement of observer agreement for categorical data. *Biometrics*. 1977; 33: 159-74.
22. Eder L, Aydin SZ, Kaeley GS, Maksymowych WP, Østergaard M. Options for assessing joints and entheses in psoriatic arthritis by ultrasonography and magnetic resonance imaging: how to move forward. *J Rheumatol Suppl*. 2018; 94: 44-7.
23. Eder L, Aydin SZ, Kaeley GS. The role of ultrasound in research and clinical practice in psoriatic arthritis: highlights from the GRAPPA ultrasound workshop. *J Rheumatol Suppl*. 2021; 97: 55-7.
24. Ayan G, Tinazzi I, Bakirci S, Gazel U, Solmaz D, Kalyoncu U, et al. Disease activity at the entheses and joints are correlated in psoriatic arthritis when explored with ultrasound. *Clin Exp Rheumatol*. 2022; 40: 44-8.
25. Smerilli G, Cipolletta E, Destro Castaniti GM, Di Matteo A, Di Carlo M, Moscioni E, et al. Doppler signal and bone erosions at the entheses are independently associated with ultrasound joint erosive damage in psoriatic arthritis. *J Rheumatol*. 2023; 50: 70-5.
26. Aguila Maldonado R, Ruta S, Valuntas ML, García M. Ultrasonography assessment of heel entheses in patients with spondyloarthritis: a comparative study with magnetic resonance imaging and conventional radiography. *Clin Rheumatol*. 2017; 36: 1811-7.
27. Di Matteo A, Cipolletta E, Destro Castaniti GM, Smerilli G, Airolidi C, Aydin SZ, et al. Reliability assessment of the definition of ultrasound enthesitis in SpA: results of a large, multicentre, international, web-based study. *Rheumatology*. 2022; 61: 4863-74.
28. Filippucci E, Smerilli G, Di Matteo A, Grassi W. Ultrasound definition of enthesitis in spon-

- dyloarthritis and psoriatic arthritis: arrival or starting point? *Ann Rheum Dis.* 2021; 80: 1373-5.
29. Helliwell PS. Assessment of enthesitis in psoriatic arthritis. *J Rheumatol.* 2019; 46: 869-70.
30. Aydin SZ, Bakirci S, Kasapoglu E, Castillo-Gallego C, Alhussain FA, Ash ZR, et al. The relationship between physical examination and ultrasonography of large entheses of the Achilles tendon and patellar tendon origin. *J Rheumatol.* 2020; 47: 1026-30.
31. Yamada Y, Inui K, Okano T, Mandai K, Mamoto K, Koike T, et al. Ultrasound assessment, unlike clinical assessment, reflects enthesitis in patients with psoriatic arthritis. *Clin Exp Rheumatol.* 2021; 39: 139-45.
32. Fiorenza A, Bonitta G, Gerratana E, Marino F, Sarzi-Puttini P, Salaffi F, et al. Assessment of enthesitis in patients with psoriatic arthritis and fibromyalgia using clinical examination and ultrasound. *Clin Exp Rheumatol.* 2020; 38: 31-9.
33. van der Ven M, Karreman MC, Weel AE, Tchvetverikov I, Vis M, Nijsten TEC, et al. Adding ultrasound to clinical examination reduced frequency of enthesitis in primary care psoriasis patients with musculoskeletal complaints. *Clin Exp Rheumatol.* 2016; 34: 1020-5.
34. Naredo E, Bijlsma JW, Conaghan PG, Acebes C, Balint P, Berner-Hammer H, et al. Recommendations for the content and conduct of European League Against Rheumatism (EULAR) musculoskeletal ultrasound courses. *Ann Rheum Dis.* 2008; 67: 1017-22.

Supplementary material available online