

# Polymyositis following varicella and mumps infection in adults: report of two cases

F. Masini<sup>1</sup>, K. Gjeloši<sup>1</sup>, E. Pinotti<sup>1</sup>, R. Ferrara<sup>1</sup>, C. Romano<sup>1</sup>, G. Cuomo<sup>2</sup>

<sup>1</sup>Department of Advanced Medical and Surgical Sciences, University of Campania Luigi Vanvitelli, Naples;

<sup>2</sup>Department of Precision Medicine, University of Campania Luigi Vanvitelli, Naples, Italy

## SUMMARY

Idiopathic immune myopathies (IIMs) are autoimmune diseases caused by immune-mediated muscle damage. The etiology remains unclear. Epidemiological and experimental studies, both in animals and humans, hint at viruses as major environmental factors able to trigger aberrant immune responses through many different mechanisms. However, only a few cases of either dermatomyositis or polymyositis following a specific viral infection have been reported in the literature. The objective of this study is to describe the clinical features and the treatment strategy of 2 cases of polymyositis developing shortly after chickenpox and mumps, respectively, and to review the existing literature on the topic.

The clinical records of the 2 patients suspected to have developed inflammatory myositis following a viral infection were reviewed. Their clinical history, main laboratory findings, and treatment outcome are presented here. Moreover, a literature search was performed in the PubMed and MEDLINE databases to identify reports describing the association between viral infections and IIMs in patients aged  $\geq 18$ .

The 2 patients reported here developed polymyositis shortly after chickenpox and mumps, respectively, suggesting a causal role for viruses in triggering autoimmunity. Only a few reports published between 1990 and 2020 were found in the literature, possibly linking infections to myositis development. Intravenous immunoglobulin and rituximab were effective for the treatment of viral-triggered polymyositis.

**Key words:** Polymyositis, varicella, mumps, viruses, intravenous immunoglobulin, rituximab.

Reumatismo, 2023; 75 (4): 202-207

## INTRODUCTION

Idiopathic immune myopathies (IIMs) are autoimmune diseases characterized by progressive weakness due to chronic muscle inflammation. Concurrent involvement of several other organs accounts for the consideration of IIMs as systemic diseases (1). Polymyositis, dermatomyositis, inclusion body myositis, and immune-mediated necrotizing myopathy are distinct subgroups of IIMs (1). Although the interplay of genetic, hormonal, and environmental factors is believed to underlie the development of autoimmunity, the pathogenesis of these conditions is far from clear (2). Infectious agents have long been suspected to be triggers of autoimmunity in a myriad of rheumatic diseases, particularly viruses such as coxsackie B virus, rotavirus, influenza A virus, herpes virus, measles, mumps,

rubella, HIV, and hepatitis B virus (2-4). Multiple mechanisms have been proposed to explain the presumed causal relationship between infection and autoimmunity. Regarding IIMs, the muscle damage typical of dermatomyositis is mediated by humoral factors directed against endomysial capillary endothelial cells, whereas cytotoxic T-cells mediate muscle fiber injury in polymyositis (5).

However, only a few cases of dermatomyositis or polymyositis following viral infections (*e.g.*, HIV, hepatitis C virus, coxsackie, and parvovirus) have thus far been reported in the literature. Therefore, we report herein 2 cases of IIMs, whose onset appeared to be suspiciously induced by infections due to varicella-zoster virus (VZV) and mumps, respectively, and discuss the role of intravenous immunoglobulin (IVIg) and rituximab as treatment options.

Corresponding author:

Francesco Masini

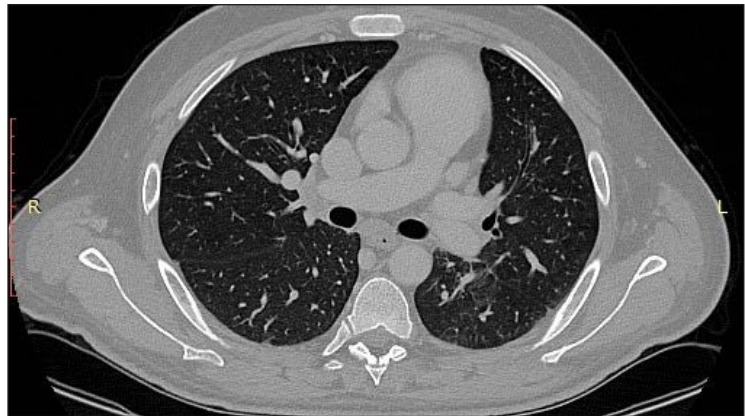
Department of Advanced Medical  
and Surgical Sciences,  
University of Campania Luigi Vanvitelli,  
Naples, Italy  
E-mail: masini.fr@gmail.com

**■ CASE REPORT 1**

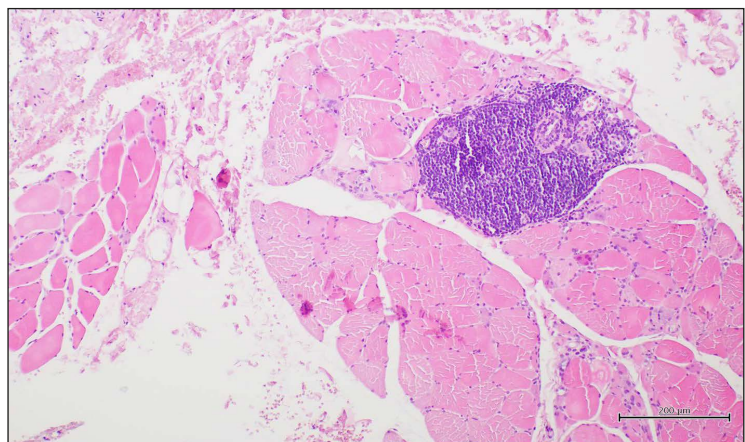
A 29-year-old otherwise healthy male patient came to our observation because of a 3-month history of hyposthenia, disabling fatigue, intense pain in the shoulder girdle muscles, and dyspnea during mild physical efforts. Just before the current complaints, he had been diagnosed with chickenpox because of fever, pharyngitis, myalgias, a quickly spreading, diffuse skin rash characterized by small, itchy blisters, and positive testing for both anti-VZV serum immunoglobulin (Ig) M antibodies and viral DNA by polymerase chain reaction in the blister fluid. Anti-viral treatment (acyclovir 800 mg orally 5 times/day for 7 days) allowed complete resolution of cutaneous manifestations; however, fatigue, pain in the shoulder girdle muscles, and hyposthenia persisted and worsened. Ptosis, dysphonia, and/or dysphagia were not reported.

Physical examination revealed bilateral upper limb muscle weakness, neck stiffness, and residual scabs on the trunk. Neither skin involvement suggesting dermatomyositis nor mechanic's hands were observed; Raynaud's phenomenon was not reported. Neurological examination demonstrated decreased proximal muscle tone and a bilateral lack of deep tendon reflexes. Laboratory tests showed increased serum levels of alanine aminotransferase (ALT 290 U/L), aspartate amino transferase (AST 490 U/L), creatine phosphokinase (CPK 11166 U/L), lactate dehydrogenase (LDH 1559 U/L), and myoglobin (MB 3746 ng/mL). Erythrocyte sedimentation rate (ESR), C-reactive protein (CRP), and other inflammatory markers were within the reference range. Thyroid function was normal. Conversely, autoimmune tests revealed elevated antinuclear antibodies (ANA) (1:5120, fine speckled pattern on HEp2 cells by indirect immunofluorescence) and positive anti-Jo-1 antibodies (EliA™, ThermoFisher, Waltham, MA, USA). Serological investigations for acute infections (hepatitis virus, cytomegalovirus, Epstein-Barr virus, herpes simplex, rubella virus, VZV, HIV, venereal disease research laboratory/treponema pallidum haemagglutination assay) were all negative. A paraneoplastic syndrome was also ruled out by

means of diagnostic procedures [contrast-enhanced total body computed tomography (CT) scan, esophagogastroduodenoscopy, colonoscopy, abdomen ultrasound]. Serum tumor markers ( $\beta_2$ -microglobulin, LDH, cancer antigen 15-3, cancer antigen 19-9, calcitonin, carcinoembryonic antigen, chromogranin A, gastrin, monoclonal immunoglobulins, prostate-specific antigen, neuron-specific enolase, tissue polypeptide antigen, cyfra 21-1) were either within the normal range or absent. A chest CT scan showed ground glass opacities in the left inferior lobe (Figure 1). Transthoracic echocardiog-



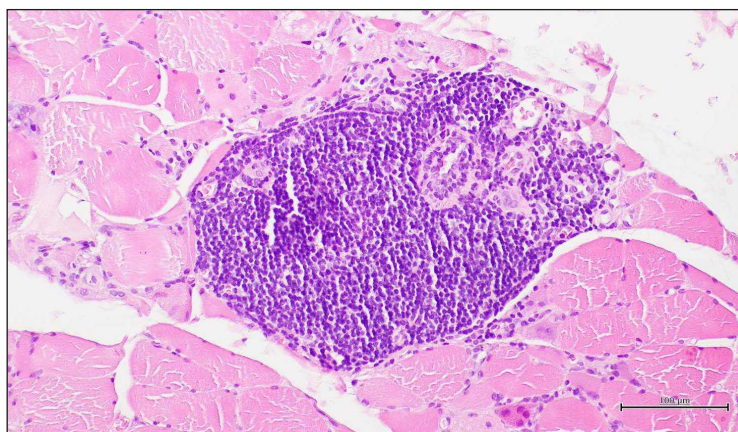
**Figure 1** - Chest computed tomography scan (axial lung window) shows ground glass opacities in the left inferior lobe.



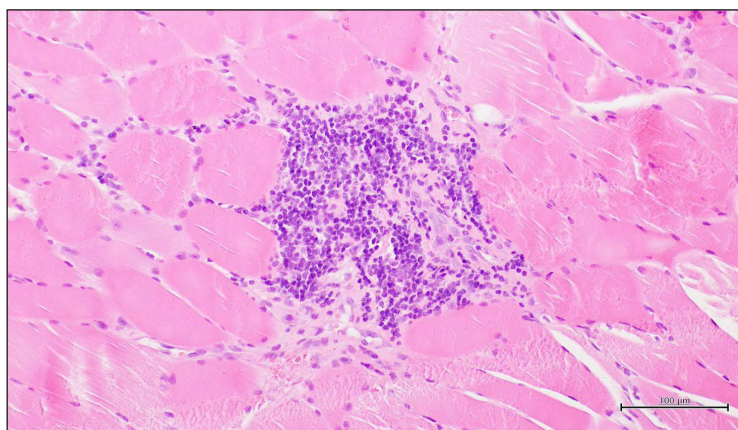
**Figure 2** - Microscopic examination of skeletal muscle shows focal infiltration of lymphocytes (right), magnification: 100x). Reproduced from Cuomo et al. (2022) with permission of *Edizioni Minerva Medica* as compared to healthy muscle fibers (left) (hematoxylin and eosin stain; original).

raphy did not reveal direct and/or indirect signs of elevated pulmonary artery pressure. Spirometry showed a reduction in both forced vital capacity (FVC=67% predicted) and diffusing capacity for carbon monoxide (DLCO=53%). Finally, a motor conduction study by means of electromyography displayed increased spontaneous activity with fibrillation, positive sharp waves, short-duration polyphasic motor units, and early recruitment, all findings consistent with inflammatory myopathy. A biopsy of the left deltoid muscle demonstrated focal endomy-

sial infiltration by mononuclear cells, muscle-cell degeneration, and fibrosis, consistent with polymyositis (Figures 2-4) (6). The patient was discharged with a definite diagnosis of polymyositis triggered by chickenpox. Methylprednisolone pulse therapy (250 mg daily for 3 days) was administered intravenously, followed by oral prednisone (1 mg/kg/day orally). In addition, mycophenolate mofetil (500 mg bid orally) and IVIg (400 mg/kg daily for 5 days) were administered. After one month, the patient reported a significant improvement in his complaints. Laboratory findings showed decreased serum levels of ALT, AST, CPK, LDH and MB (82 U/L, 75 U/L, 2802 U/L, 816 U/L, and 1150 ng/mL, respectively) and ANA titers (1:160, fine speckled pattern), while anti-Jo-1 antibodies remained positive. Complete disease remission was obtained shortly thereafter and maintained, as assessed at regular, 3-monthly follow-up visits.



**Figure 3** - Higher magnification shows infiltration of lymphocytes, with some myofibers displaying myopathic features (small, pale and degenerating) (hematoxylin and eosin stain; original magnification: 200×). Reproduced from Cuomo et al. (2022) with permission of *Edizioni Minerva Medica*.



**Figure 4** - Lymphocytes invading muscle fibers (hematoxylin and eosin stain; original magnification: 200×). Picture courtesy of Prof. Renato Franco and Dr. Francesca Pagliuca, Department of Mental Health and Physical and Preventive Medicine, Luigi Vanvitelli University of Campania, Naples, Italy.

## ■ CASE REPORT 2

An otherwise healthy 44-year-old female presented for evaluation of progressive fatigue and muscle weakness. 4 weeks earlier, she developed fever and parotid and eyelid swelling. Mumps infection was supposed and confirmed by the positivity of mumps-specific IgM and IgG serum antibodies. Analgesic treatment (ibuprofen 600 mg/day orally for 6 days) was begun, with immediate symptomatic relief. However, one month later, she experienced generalized muscle aching and arthralgias in her hands, unresponsive to non-steroidal anti-inflammatory drugs.

Physical examination revealed decreased proximal muscle tone and a bilateral lack of deep tendon reflexes. No skin involvement was noted, mechanic's hands were not observed, and Raynaud's phenomenon was not a complaint. Laboratory tests were relevant for increased serum levels of ALT (152 U/L), AST (110 U/L), CPK (2153 U/L), LDH (539 U/L), and MB (1172 ng/mL). ESR, CRP and other inflammatory markers were within the normal range; thyroid function was preserved. Autoimmune tests disclosed ANA (1:80, fine speckled pattern on HEp2 cells by

indirect immunofluorescence), anti-smooth muscle antibodies (ASMA 1:80), and positive anti-Jo-1 (EliA™, ThermoFisher, Waltham, MA, USA); anti-acetylcholine receptor antibodies were absent. A paraneoplastic syndrome was ruled out by means of the same diagnostic investigations reported for case report 1. A diffuse inflammation of the parotid glands was observed. Tumor markers were unrevealing. High-resolution chest CT scan showed peripheral, sub-pleural, predominantly basal reticulations. Spirometry revealed a reduction in the DLCO (56%), with 70% FVC.

A motor conduction study showed increased spontaneous activity with fibrillation, positive sharp waves, and low-amplitude polyphasic units of short duration. A biopsy of the anterior left tibialis muscle demonstrated changes compatible with chronic inflammation with mononuclear cells infiltrating the endomysium. These findings were consistent with polymyositis, possibly triggered by mumps.

The patient was started on pulse intravenous methylprednisolone therapy (250 mg daily for three days), followed by oral prednisone (1 mg/kg/day orally). In addition, mycophenolate mofetil (500 mg bid orally) and IVIg (400 mg/kg daily for 5 days for 5 cycles) were administered. Over the course of the following 5 months, she noted increasingly difficult exertion and exertional dyspnea, with serum CPK still being elevated

(3900 U/L) despite the treatment. Consequently, i.v. rituximab (1000 mg repeated after 14 days, followed by a third infusion at 6 months) was started, with progressive improvement in her symptoms and declining CPK levels (1237 U/L). At the time of this report, oral prednisone was being tapered (25 mg/day at the latest follow-up), with no disease relapse.

## ■ DISCUSSION AND CONCLUSIONS

IIMs are a group of inflammatory myopathies caused by immune-mediated muscle damage. The etiology of autoimmune diseases remains unclear. Epidemiological and experimental studies, both in animals and humans, hint at viruses as major environmental factors able to trigger aberrant immune responses through many different mechanisms, including modifications of self-antigens, release of clustered host antigens, display of cryptic epitopes, molecular mimicry, etc. (2, 5). Several infectious agents have been suggested as etiologic agents in IIMs (Table I) (3, 4, 7, 8); for instance, the human retroviruses HIV and human T-cell leukemia-lymphoma virus type 1 can be associated with chronic, immune-mediated inflammatory myositis (7); moreover, Coxsackie-B virus RNA has been found in muscles from both dermatomyositis and polymyositis patients, while Parvo-

**Table I** - List of reports describing the association between viral infections and idiopathic immune myopathies.

Author	Year	Number of patients reported	Type of viral infection	Type of IIMs	Therapy	Reference
Bowles et al.	1987	4	Coxsackie-B	Dermatomyositis and polymyositis	Steroids	(7)
Chevreil et al.	2000	1	Parvovirus B19	Dermatomyositis	Prednisone 20 mg daily+methotrexate 12.5 mg/week	(8)
Carroll and Holmes	2011	1	Human immunodeficiency virus	Dermatomyositis	Prednisone 1 mg/kg daily	(4)
Chou et al.	2017	1	Hepatitis B virus	Dermatomyositis	Steroids	(3)

IIMs, idiopathic immune myopathies.

virus B19 DNA has been reported within muscle biopsies of a dermatomyositis patient (8, 9). Conversely, Fox et al. (10) examined muscle biopsy specimens from 18 patients with inclusion body myositis, finding no evidence of mumps virus RNA. Nevertheless, our 2 case reports and the lack of data about the prevalence of myositis following mumps and VZV infections should warrant further investigations into the association of IIMs with these infectious agents as possible triggers. Moreover, since molecular mimicry has already been reported between host and microbial proteins, including similarities between Jo-1 synthetase and EBV ECRF4 protein or alanyl-tRNA synthetase and adenovirus (5), EBV, and influenza proteins, it would be interesting to investigate the possibility of molecular mimicry between host muscle proteins and both VZ and mumps viral proteins.

Based on the International Myositis Classification Criteria Project (IMCCP), the Bohan and Peter criteria for dermatomyositis and polymyositis, and the European League Against Rheumatism and American College of Rheumatology (EULAR/ACR) IIM classification criteria (11-13), both clinical cases illustrated above were diagnosed as polymyositis. The classification criteria for myositis have some limitations due to a lack of up-to-date data. Bohan and Peter criteria, indeed, do not specify how to classify patients with infectious myopathy or drug-associated myopathy. The IMCCP criteria perform better than the previous ones in sensitivity, specificity, and accuracy. Moreover, since IIMs are a heterogeneous group of diseases with multiple organ involvement, overlapping features, and different molecular mechanisms, categorization remains challenging. Certain characteristic histological findings may also appear late in the disease course, leading to the misclassification of patients. According to the EULAR/ACR criteria, certain IIM subsets, such as the anti-synthetase syndrome, still remain in the polymyositis category despite a distinct phenotype and clinical course (14). Therefore, because of ongoing improvements in diagnosis, a periodic revision of classification criteria is warranted.

IVIg therapy is considered an effective therapy for dermatomyositis and polymyositis. Significant improvements in muscle strength and muscle biochemistry, as well as a steroid-sparing effect, have been reported in many patients refractory to initial treatment (15). Rituximab, a B-cell-depleting monoclonal antibody, has also shown effectiveness and a steroid-sparing effect in certain subsets of polymyositis/dermatomyositis refractory to prednisone and immunosuppressants (16). Although there is no evidence for IVIg and rituximab as specific treatments for virus-triggered myositis, these cases support the use of these agents to achieve control of immune-mediated myositis triggered by viral infections. Clearly, our conclusions are mainly based on the temporal association between the diagnosis of a viral infection and myositis onset. Therefore, the limitations of our observations lie in the low number of patients reported, the lack of genetic studies to assess patient predisposition to autoimmunity, and the lack of molecular studies to prove the causal relationship between viral infection and polymyositis. Nevertheless, our case reports add further evidence to the role of viruses as triggers of autoimmunity.

### Contributions

FM, project development, data collection, manuscript writing; KG, project development, manuscript writing; EP, data collection, manuscript writing; RF, data collection; CR, draft review; GC, project development.

### Conflict of interest

The authors declare that they have no competing interests, and all authors confirm accuracy.

### Ethics approval and consent to participate

No ethical committee approval was required.

### Informed consent

Both patients gave their informed consent for off-label treatment of their conditions. The authors guarantee the anonymity of patients.

## Funding

None.

## Availability of data and materials

Data available from the corresponding author upon request.

## REFERENCES

1. Baig S, Paik JJ. Inflammatory muscle disease - an update. *Best Pract Res Clin Rheumatol.* 2020; 34: 101484.
2. Smatti MK, Cyprian FS, Nasrallah GK, Al Thani AA, Almishal RO, Yassine HM. Viruses and autoimmunity: a review on the potential interaction and molecular mechanisms. *Viruses.* 2019; 11: 762.
3. Chou JW, Lin YL, Cheng KS, Wu PY, Ju TR. Dermatomyositis induced by hepatitis B virus-related hepatocellular carcinoma: a case report and review of the literature. *Intern Med.* 2017; 56: 1831-7.
4. Carroll MB, Holmes R. Dermatomyositis and HIV infection: case report and review of the literature. *Rheumatol Int.* 2011; 31: 673-9.
5. Zampieri S, Ghirardello A, Iaccarino L, Briani C, Sarzi-Puttini P, Atzeni F, et al. Polymyositis-dermatomyositis and infections. *Autoimmunity.* 2006; 39: 191-6.
6. Cuomo G, Iagnocco A. *Manuale di reumatologia.* Turin: Minerva Med. 2022. [Book in Italian].
7. Ytterberg SR. Infectious agents associated with myopathies. *Curr Opin Rheumatol.* 1996; 8: 507-13.
8. Bowles NE, Dubowitz V, Sewry CA, Archard LC. Dermatomyositis, polymyositis, and Coxsackie-B-virus infection. *Lancet.* 1987; 1: 1004-7.
9. Chevrel G, Calvet A, Belin V, Miossec P. Dermatomyositis associated with the presence of parvovirus B19 DNA in muscle. *Rheumatology.* 2000; 39: 1037-9.
10. Fox SA, Ward BK, Robbins PD, Mastaglia FL, Swanson NR. Inclusion body myositis: investigation of the mumps virus hypothesis by polymerase chain reaction. *Muscle Nerve.* 1996; 19: 23-8.
11. Leclair V, Lundberg IE. New myositis classification criteria-what we have learned since Bohan and Peter. *Curr Rheumatol Rep.* 2018; 20: 18.
12. Lundberg IE, Tjärnlund A, Bottai M, Werth VP, Pilkington C, de Visser M, et al. 2017 European League Against Rheumatism/American College of Rheumatology classification criteria for adult and juvenile idiopathic inflammatory myopathies and their major subgroups. *Ann Rheum Dis.* 2017; 76: 1955-64.
13. Sasaki H, Kohsaka H. Current diagnosis and treatment of polymyositis and dermatomyositis. *Mod Rheumatol.* 2018; 28: 913-21.
14. Baccaro ACCD, Behrens Pinto GL, Carboni RCS, Shinjo SK. The clinical manifestations at the onset of antisynthetase syndrome: a chameleon with multiple faces. *Reumatismo.* 2020; 72: 86-92.
15. Goswami RP, Haldar SN, Chatterjee M, Vij P, van der Kooi AJ, Lim J, et al. Efficacy and safety of intravenous and subcutaneous immunoglobulin therapy in idiopathic inflammatory myopathy: a systematic review and meta-analysis. *Autoimmun Rev.* 2022; 21: 102997.
16. Barsotti S, Cioffi E, Tripoli A, Tavoni A, D'Ascanio A, Mosca M, et al. The use of rituximab in idiopathic inflammatory myopathies: description of a monocentric cohort and review of the literature. *Reumatismo.* 2018; 70: 78-84.