

# Three-dimensional morphological condylar and mandibular changes in a patient with juvenile idiopathic arthritis: interdisciplinary treatment

G. Farronato<sup>1</sup>, C. Bellintani<sup>2</sup>, U. Garagiola<sup>1</sup>, P. Cressoni<sup>1</sup>, P. Sarzi Puttini<sup>3</sup>, F. Atzeni<sup>3</sup>, M. Cazzola<sup>4</sup>

<sup>1</sup>Department of Orthodontics, Dental Clinic, University of Milan;

<sup>2</sup>Immunorheumatology Service, AO Sant'Antonio Abate, Gallarate (VA);

<sup>3</sup>Rheumatology Unit, Luigi Sacco University Hospital, Milan;

<sup>4</sup>Unit of Rehabilitation Medicine, "Ospedale di Circolo" Busto Arsizio, Presidio di Saronno, Saronno (VA), Italy

## SUMMARY

Temporomandibular joint (TMJ) involvement is common but usually delayed in patients with juvenile idiopathic arthritis (JIA). We describe the case of a JIA patient with bilateral TMJ involvement, mandibular retrognathia, bone erosion, and severely restricted mouth opening. The use of cone beam computed tomography and a 3D diagnostic protocol in young patients with JIA provides reliable, accurate and precise quantitative data and images of the condylar structures and their dimensional relationships. Analgesics and conventional disease modifying antirheumatic drugs were ineffective, but interdisciplinary treatment with etanercept and a Herbst functional appliance improved functional TMJ movement and bone resorption.

**Key words:** Temporomandibular joint, Juvenile idiopathic arthritis, Etanercept.

Reumatismo, 2014; 66 (3): 254-257

## INTRODUCTION

Juvenile idiopathic arthritis (JIA) is a multiform, autoimmune clinical syndrome that affects genetically predisposed patients aged <16 years and is characterized by synovitis and inflammation of the joints, tendons, tendon sheaths and ligaments (1).

Its annual floating incidence is 50-110 cases per 100,000 children, which makes it the most common chronic disease of childhood that can lead to the serious and persistent impairment of one or more joints and consequent disability. The joint damage is usually more severe than that observed in the adult form because it affects joints during their phase of growth (1).

Temporomandibular joint (TMJ) involvement is often asymptomatic and, unless treated early, can lead to severe craniofacial growth disturbances and facial deformities.

However, TMJ arthritis in JIA patients is difficult to diagnose at an early stage because it has few symptoms and signs (2, 3).

## CASE REPORT

This 13-year-old boy, whose extensive oligoarticular JIA (4) had been treated with methotrexate (MTX) 15 mg/m<sup>2</sup>/week (5) from the age of six, was brought to our attention in January 2010 because of the recent onset of joint lock, reduced mouth opening, and pain whilst chewing. Clinical examination revealed severe mandibular retrognathia (Fig. 1), a reduced range of motion with a maximum opening of only 10 mm, pain upon bilateral palpation of TMJ, and concomitant acute pain in the wrist and left knee. The disease was only partially controlled, and the patient had high levels of C-reactive protein (CRP)

Corresponding author:

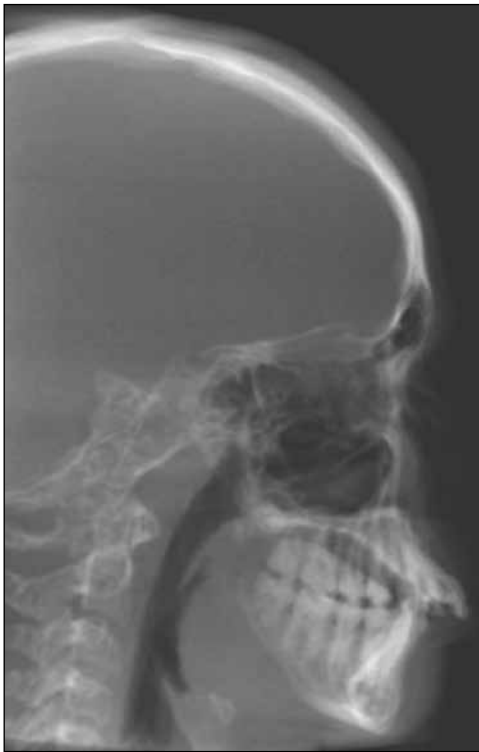Claudio Bellintani

Immunoreumatologia Azienda

Ospedaliera Sant'Antonio Abate

Largo Pastori, 4 - 21013 Gallarate (VA), Italy

E-mail: bellintani.claudio@libero.it



**Figure 1** - Severe mandibular retrognathia and proalveolia of the upper arch.

and a high erythrocyte sedimentation rate (ESR).

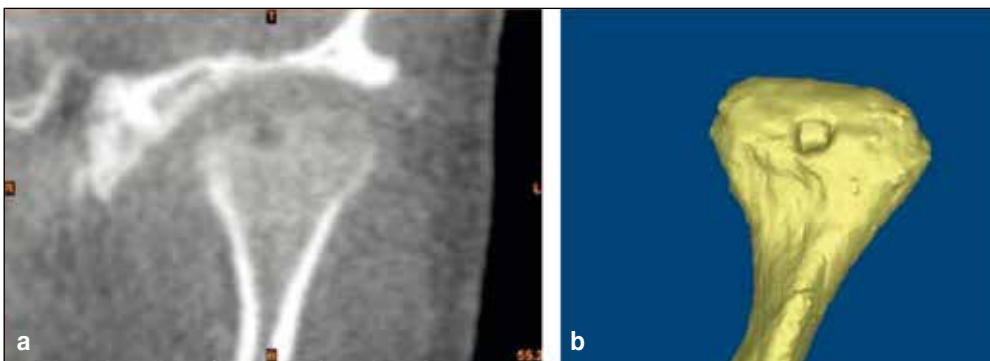
Radiography of the dental arches revealed no particular defects, but three-dimensional (3D) cone beam computed tomography (CBCT) highlighted bilateral involvement of the TMJ with the complete absence of translational movement and severe bone erosion of the mandibular condyle and glenoid fossa (Fig. 2) (6).

The patient was diagnosed as having temporomandibular arthritis in active JIA unresponsive to MTX. He was given a Herbst appliance (Fig. 3), prescribed treatment with etanercept 0.7 mg/kg/week (7), and asked to attend monthly follow-up examinations.

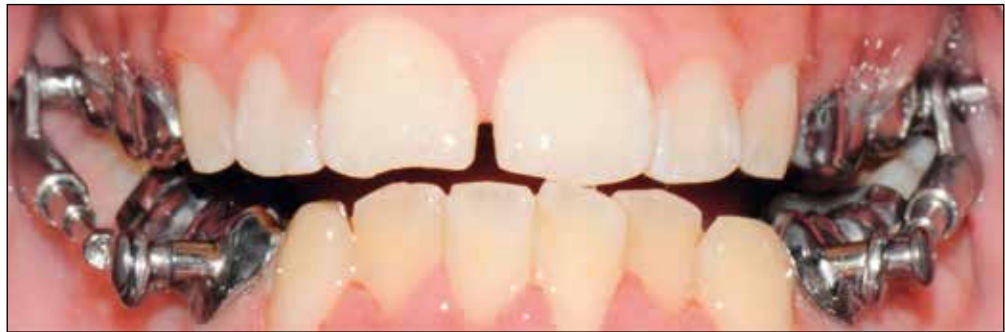Disease remission was obtained in March 2011: the patient's mouth opening had significantly improved to reach an inter-incisor distance of 32 mm, there was no pain when chewing, and his ESR and CRP levels had normalized. The Herbst appliance was removed, and CBCT showed correction of the retrognathia (Fig. 4), with new bone apposition and remodeling of the condyle and glenoid fossa of the left TMJ (Fig. 5) (8).

#### ■ DISCUSSION AND CONCLUSIONS

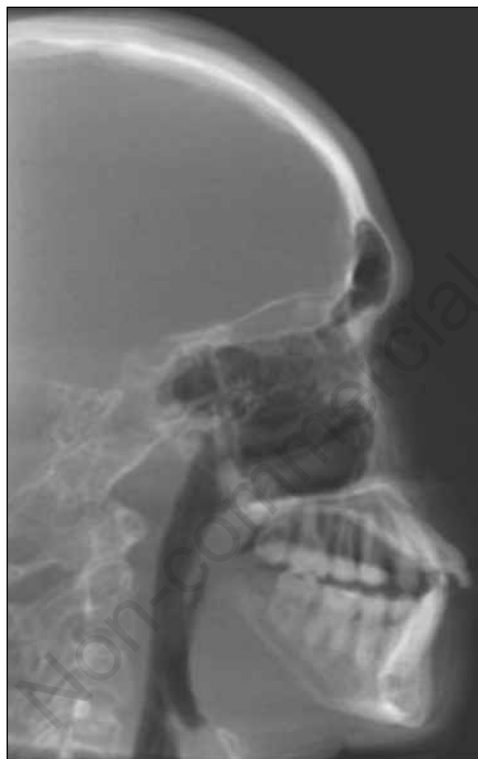This report describes three-dimensional volumetric changes in the mandible due to combined therapy with etanercept and Herbst appliance (9) in a patient with JIA complicated by mandibular retrognathia. The use of CBCT and the 3D diagnostic protocol in young patients with JIA provides reliable, accurate and precise quantitative data and images of the condylar structures and their dimensional relationships. The datasets were superimposed on the basis of the anatomical structures at the base of the cranium, and the mandible was superimposed on the basis of the mandibular symphysis and the lower mandibular



**Figure 2** - A) Cone beam computed tomography image of condyle erosion of the left temporomandibular joint; B) three-dimensional reconstruction of the affected condyle.

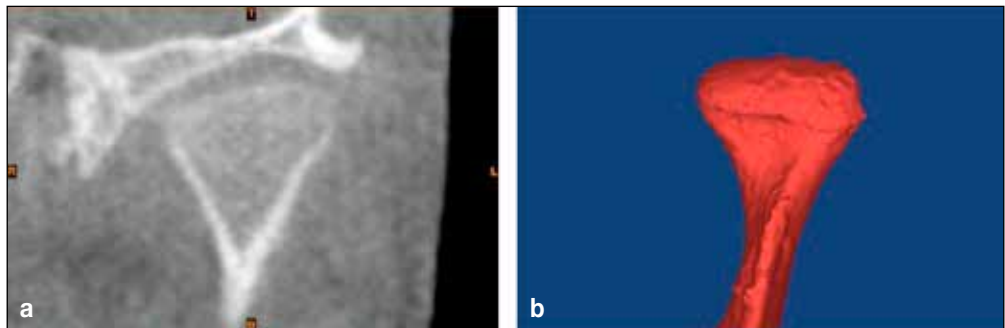


**Figure 3** - Herbst appliance during function.



◀ **Figure 4** - Cone beam computed tomography image showing correction of the retrognathia at the end of orthodontic treatment.

border. The results showed that the mandible had moved forward and downward in relation to the anterior cranial base. In addition, bone apposition was observed on almost all of the surfaces of both mandibular condyles and the roof of the glenoid fossa. TMJ involvement is often asymptomatic in patients with JIA, and can lead to severe craniofacial growth disturbances and facial deformities if left untreated (10). However, early TMJ arthritis is difficult to diagnose in JIA patients because of the relatively few symptoms and clinical findings (11, 12) and the fact that none of the clinical signs or symptoms of TMJ dysfunction are predictors of bony destruction. Consequently, the pathological process can affect growth long before any radiographic changes can be seen, and early collaboration between dentists and rheumatologists is very impor-



**Figure 5** - A) Cone beam computed tomography of the left temporomandibular joint after medical and orthodontic; B) three-dimensional reconstruction of new bone formation and treatment condyle remodelling.

tant (13, 14). In addition to exercise and local pain treatment, dentists should recommend an occlusal splint to help to keep the TMJs working properly, improve function, relieve pain, reduce swelling, and prevent further severe damage (3).

In addition to clinical and laboratory findings, CBCT is useful in diagnosing and treating early JIA. Patients with CBCT-positive TMJ damage cannot be identified by means of a simple clinical examination, whereas CBCT can quantify morphological changes of the condyle and mandible (15).

In comparison with CBCT, magnetic resonance imaging (MRI) takes longer and can be difficult in the case of patients who are unable to sit (or be held) still for a long period of time, which means that children (particularly young children) may require general anesthesia or conscious sedation. MRI is the gold standard for a diagnosis of the temporomandibular disk, but the use of CBCT and the 3D diagnostic protocol in young patients with JIA enables reliable, accurate and precise quantitative and volumetric imaging of the condylar and mandibular structures and their dimensional relationships.

## ■ REFERENCES

1. Petty RE, Southwood TR, Manners P, Baum J, Glass DN, Goldberg J, et al. International League of Associations for Rheumatology classification of juvenile idiopathic arthritis: second revision, Edmonton, 2001. *J Rheumatol.* 2004; 31: 390-2.
2. Larheim TA, Höyeraal HM, Stabrun AE, Haanaes HR. The temporomandibular joint in juvenile rheumatoid arthritis. Radiographic changes related to clinical and laboratory parameters in 100 children. *Scand J Rheumatol.* 1982; 11: 5-12.
3. Bellintani C, Ghiringhelli P, Gerloni V, Gattinara M, Farronato G, Fantini F. Temporomandibular joint involvement in juvenile idiopathic arthritis: treatment with an orthodontic appliance. *Reumatismo.* 2005; 57: 201-7.
4. Oen KG, Cheang M. Epidemiology of chronic arthritis in childhood. *Semin Arthritis Rheum.* 1996; 26: 575-91.
5. Giannini EH, Brewer EJ, Kuzmina N, Shaikov A, Maximov A, Vorontsov I, et al. Methotrexate in resistant juvenile rheumatoid arthritis. Results of the U.S.A.-U.S.S.R. double-blind, placebo-controlled trial. The Pediatric Rheumatology Collaborative Study Group and The Cooperative Children's Study Group. *N Engl J Med.* 1992; 326: 1043-9.
6. Farronato G, Garagiola U, Carletti V, Cressoni P, Bellintani C. Psoriatic arthritis: temporomandibular joint involvement as the first articular phenomenon. *Quintessence Int.* 2010; 41: 395-8.
7. Nielsen S, Ruperto N, Simonini G, Alpigiani MG, Barcellona R, Gerloni V, et al. Preliminary evidence that etanercept is more effective than methotrexate in suppressing inflammation and in reducing radiographic progression in JIA. *ACR Annual Meeting 2005*; S82: abs. 128.
8. Gianni E. *La nuova ortognatodonzia.* Padova: Piccin Editore. 1986.
9. Takei S, Groh D, Bernstein B, Shaham B, Gallagher K, Reiff A. Safety and efficacy of high dose etanercept in treatment of juvenile rheumatoid arthritis. *J Rheumatol.* 2001; 28: 1677-80.
10. Mortellaro C, Rimondini L, Farronato G, Garagiola U, Varcellino V, Berrone M. Temporomandibular disorders due to improper surgical treatment of mandibular fracture: clinical report. *J Craniofac Surg.* 2006; 17: 373-82.
11. Bowyer SL, Roettcher PA, Higgins GC, Adams B, Myers LK, Wallace C, et al. Health status of patients with juvenile rheumatoid arthritis at 1 and 5 years after diagnosis. *J Rheumatol.* 2003; 30: 394-400.
12. Reynolds M, Reynolds M, Adeeb S, El-Bialy T. 3-d volumetric evaluation of human mandibular growth. *Open Biomed Eng J.* 2011; 5: 83-9.
13. Farronato G, Garagiola U, Dominici A, Periti G, de Nardi S, Carletti V, et al. "Ten-point" 3D cephalometric analysis using low-dosage cone beam computed tomography. *Prog Orthod.* 2010; 11: 2-12.
14. Farronato G, Garagiola U, Carletti V, Cressoni P, Mercatali L, Farronato D. Change in condylar and mandibular morphology in juvenile idiopathic arthritis: cone beam volumetric imaging. *Minerva Stomatol.* 2010; 59: 519-34.
15. Kapila S, Conley RS, Harrell WE Jr. The current status of cone beam computed tomography imaging in orthodontics. *Dentomaxillofac Radiol.* 2011; 40: 24-34.